

# Immature spermatids are not prevalent in semen from men who are receiving androgen-based contraceptive regimens

Yang Zhengwei, M.Sc.,\* Nigel G. Wreford, Ph.D.,† William J. Bremner, M.D.,‡  
Alvin M. Matsumoto, M.D.,‡ Bradley A. Anawalt, M.D.,‡ and Robert I. McLachlan, M.D.\*

Prince Henry's Institute of Medical Research, Monash Medical Centre, Institute of Reproduction and Development, Monash University, Monash Medical Centre, Clayton, Victoria, Australia, and Veterans Affairs, Puget Sound Health Care System, and Department of Medicine, University of Washington, Seattle, Washington

**Objective:** To determine whether immature spermatids increase in semen in response to hormonal contraceptive treatments. Such a finding would support the existence of a defect in spermiogenesis, which in turn may explain the reported variability in sperm output.

**Design:** Semen smears were obtained from healthy men undergoing randomized control trials of T plus progestin contraceptive treatments.

**Patient(s):** Healthy men (21–49 years) with normal semen analyses received T (50–100 mg IM weekly) in combination with either desogestrel (150–300 µg daily,  $n = 5$ ) or levonorgestrel (125–250 µg daily,  $n = 10$ ) for 24 weeks. Semen smears were made during spermatogenic suppression and recovery. Nine control subjects were also assessed.

**Main Outcome Measure(s):** Semen analyses were performed using World Health Organization criteria. Immature spermatids and white blood cells in semen were identified by immunostaining with monoclonal antibodies to the human intra-acrosomal antigen SP-10 and the ubiquitous white cell CD-45 antigen, respectively.

**Result(s):** In a total of 14 normal ejaculates (9 control and 5 pretreatment)  $74 \pm 14$  million/mL sperm (mean  $\pm$  SEM) were seen together with a few immature spermatids ( $0.69 \pm 0.20$  million/mL). During contraceptive treatments, spermatid number decreased in parallel with the sperm concentration and spermatids disappeared in most subjects. No significant changes were seen in either leukocyte or immunonegative round cell concentration ( $0.41 \pm 0.25$  and  $0.25 \pm 0.09$  million/mL in controls, respectively) in response to treatments.

**Conclusion(s):** Spermatid sloughing, as assessed by the ejaculation of immature spermatids, is not a feature of T-induced spermatogenic regression in men; rather, the decline in both mature and immature germ cells in the ejaculate probably results from a decline in the number of precursor cells, ultimately resulting in severe oligo- or azoospermia. Detailed studies on the sites of spermatogenic interruption are required to understand the variability in responses seen after contraceptive therapies in men. (Fertil Steril® 1998;69:89–95. ©1998 by American Society for Reproductive Medicine.)

**Key Words:** Progestin, semen, sperm, spermatids, testosterone, leukocytes, acrosome

It has long been recognized that exogenous T or progestins inhibit spermatogenesis in men (1, 2). In the 1970s, after the successful use of progestins as a contraceptive in women, work

on developing a male hormonal contraceptive began using T, alone or in combination with progestins, to reversibly suppress serum gonadotropin levels and thereby spermatogenesis.

Received May 23, 1997;  
revised and accepted  
August 12, 1997.

This study was supported by the Contraception 21 Grant of the Rockefeller Foundation, the Australian NH&MRC Grant 943208, the CONRAD Program, NIH grant HD 12926, and the Andrew W. Mellon Foundation.

Reprint requests: Dr. R.I. McLachlan, Prince Henry's Institute of Medical Research, P.O. Box 5152, Clayton, Victoria, Australia, 3168 (FAX: 61-3-95506125; e-mail: Rob.MacLachlan@med.monash.edu.au).

\* Prince Henry's Institute of Medical Research, Monash Medical Centre, Clayton, Victoria, Australia, 3168.

† Institute of Reproduction and Development, Monash University, Monash Medical Centre, Clayton, Victoria, Australia, 3168.

‡ Veterans Affairs, Puget Sound Health Care System, and Department of Medicine, University of Washington, 1660 S. Columbian Way, Seattle, WA 98108, U.S.A.

0015-0282/98/\$19.00  
PII S0015-0282(97)00426-3

Although severe oligospermia or azoospermia were shown to be reversibly induced in the majority of subjects (3–7), the degree of spermatogenic suppression was variable. Suppression to azoospermia was achieved in ~60% of white men but in ~95% of Asians (5). In addition, the time taken to achieve suppression of sperm output varied between subjects. The sites in the spermatogenic process inhibited by androgen/progestin treatment are unclear as are the basis for the varying rates and the degree of spermatogenic suppression seen within and between racial groups (5–9).

In the rat, T treatment suppresses LH and testicular testosterone levels and consequently, spermatogenesis. The principle spermatogenic lesion in this setting is the inhibition of round to elongated spermatid maturation (10), with the apparent sloughing of stage VIII spermatids from the seminiferous epithelium resulting in their appearance in the epididymis (11). It is not clear whether the same process occurs in men.

Several early studies reported that treatment of normal men with 6-medroxy-progesterone acetate (12) or combinations of danazol and T (13) increased the number of round (immature) spermatids in the semen. Normal human semen may contain, in addition to spermatozoa, round nucleated germ cells, inflammatory cells (leukocytes), and other cells (e.g., macrophages and epithelial cells). The identification of these cell types by light microscopy in semen smears using conventional staining has been difficult, particularly the differentiation of round spermatids from lymphocytes/monocytes, and of spermatid symplasts (with two or more nuclei in a common cytoplasm) from polymorphonuclear granulocytes. Recently, this task has been facilitated by immunocytologic techniques using monoclonal antibodies against acrosomal and leukocyte antigens (14–18).

In the present study, we used immunocytochemical staining with monoclonal antibodies to the human intra-acrosomal SP-10 antigen (17) and the common CD-45 human leukocyte antigen to assist in cellular identification in human semen. We attempted to determine whether there were increased numbers of immature spermatids and leukocytes in semen after gonadotropin withdrawal induced by T administration, in combination with progestins, for the purposes of contraception. Such a finding would suggest that sloughing of maturing germ cells previously described in rodents also occurs in men. The variability in the degree of sloughing could explain the observed variations in the rate and completeness of spermatogenic suppression in human contraceptive regimens.

## MATERIALS AND METHODS

### Hormonal Treatments and Sample Collection

All men enrolled in the study were in good health and were 21–49 years of age. All had at least two normal pretreatment analyses of semen; semen samples were col-

lected by masturbation after at least 24 hours of abstinence and assessed using the World Health Organization criteria (19). All had normal serum T, LH, and FSH levels. Institutional Review Board approval for these studies was obtained from the Human Subjects Committee of the University of Washington. The study included three groups of subjects.

### Testosterone Plus Desogestrel

Five men received testosterone plus desogestrel enanthate IM for 22–24 weeks. Two men received desogestrel (150  $\mu\text{g}$  daily plus T [100 mg/week]), two received desogestrel (300  $\mu\text{g}$  daily plus T [100 mg/week]), and one received (150  $\mu\text{g}$  daily plus T [50 mg/week]). Semen samples were collected before the treatment and every 2–4 weeks for the first 12 weeks.

### Testosterone Plus Levonorgestrel

Ten men received levonorgestrel (250  $\mu\text{g}$ ,  $n = 4$ ; or 125  $\mu\text{g}$ ,  $n = 6$ ) plus T 100 mg IM weekly for 24 weeks. Before cessation of treatment (19–24 weeks), semen samples were collected from four men (suppression phase) and semen samples were collected from the other six men 1–8 weeks after the cessation of treatment (recovery phase).

### Normal Control Group

Semen was also collected from nine healthy men.

### Preparation of Semen Smears

After routine semen analysis using the World Health Organization criteria (19), liquefied semen (0.1–1.0 mL) was centrifuged three times (600 g, 10 minutes each time) and washed in phosphate buffered saline (PBS, 0.01 mol/L, pH 7.20). The final pellet was resuspended in PBS to ~10 million spermatozoa/mL if possible, otherwise the pellet was resuspended in a minimal volume. The final suspension (5  $\mu\text{L}$ ) was applied to a precleaned microscope slide (Labcraft, Dallas, TX). The slides were then dried, fixed with acetone for 10 minutes, and stored at  $-80^{\circ}\text{C}$  in a sealed box with a desiccant (silica gel beads).


### Immunocytochemical Staining

#### Procedures

The slides were stained with an indirect immunoperoxidase method (20) at room temperature. The main steps were [1] 0.1% hydrogen peroxide in distilled water was applied for 15 minutes to quench endogenous peroxidase activity; [2] a serum-free protein block (Dako, Carpinteria, CA) was applied for 15 minutes to saturate nonspecific binding sites; [3] incubation for 30 minutes with either the monoclonal antibody against human intra-acrosomal antigen SP-10 [SP-10–3mAbs (Virginia Biotech, Charlottesville, VA), 1:50 in PBS containing 0.5% bovine serum albumin (BSA)], or against the cell membrane located human leukocyte common antigen CD-45 [T29/33 (Dako), 1:50 in PBS containing 0.5% BSA], or with PBS (as control); [4] peroxidase-conju-

## FIGURE 1

Light micrographs of immunostained spermatids in 4- $\mu\text{m}$ -thick paraffin-embedded testicular sections from a normal adult man. The primary antibody used in the staining was a monoclonal antibody against the human intra-acrosomal antigen SP-10. The immunopositive area is brown. G, Golgi phase round spermatid; C, cap phase round spermatid; E, early acrosome phase spermatid; L, late acrosome phase spermatid. Bar = 10  $\mu\text{m}$ .



gated immunoglobulins (goat anti-mouse, Dako; 1:50 in PBS containing 0.5% BSA) for 15 minutes; [5] 3,3'-diaminobenzidine tetrahydrochloride [Sigma, St. Louis, MO; 10 mg dissolved in 15 mL of Tris/HCl buffer (pH 7.4) containing 12  $\mu\text{L}$  30% hydrogen peroxide for 15 minutes to develop the immunoreaction product. Finally the slides were counterstained with Harris' hematoxylin (Sigma) for 10 seconds, blued with Scott's tap water, dehydrated with ethanol, cleared with histolene (Fronine, New South Wales, Australia), and mounted under DPX (BDH, Poole, UK).

### Control Samples

Several control samples were used to ensure the specificity of the monoclonal antibody-based identification methods. [1] Normal human testicular biopsy tissue blocks were immersion fixed in Bouin's fluid, embedded in paraffin, and sectioned at 4  $\mu\text{m}$ . The sections were immunostained using the same method as for the semen smears. This served as a positive control for the staining of immature spermatids. [2] Semen smears from two patients undergoing infertility investigations who were found to contain numerous round cells presumed to be immature spermatids. These smears were also used as a positive control for the staining of immature spermatids. [3] A smear of normal human leukocytes was obtained from the leukocyte-rich layer of blood after centrifugation and served as a positive control for the CD-45 staining procedure.

### Cellular Identification Criteria

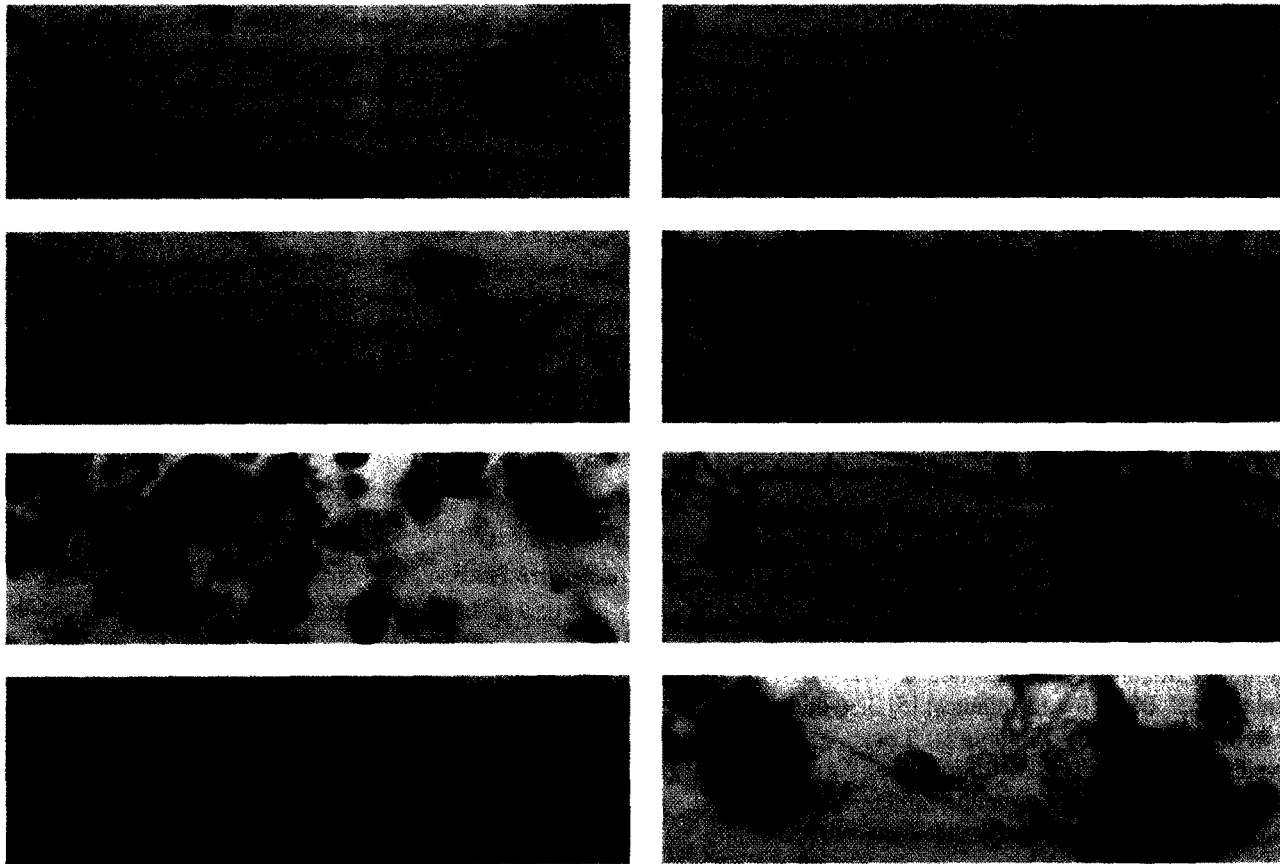
Separate smears were stained with SP-10 or CD-45 monoclonal antibodies to enable the counting of sperm/immature spermatids and leukocytes, respectively. As slides were not costained, the concentration of non-CD-45-positive round cells was also determined in the smears stained with CD-45 antibody. The number of round cells negative to both SP-10 and CD-45 was then derived by subtracting the number of SP-10-positive round cells from the number of CD-45-negative round cells.

Mature spermatozoa were readily identified on morphologic criteria irrespective of their SP-10 immunoreactivity. SP-10 immunoreactivity (fine brown granules) was seen in the acrosome or acrosomic system of immature spermatids (Figures 1 and 2). The immature spermatids in the seminal smear were identified provided that the nucleus was seen and a dot, patch, or crescent-shaped SP-10 immunoreactive area was apparent in the cytoplasm or nucleus.

Immature spermatids were divided into three phases based on the description of Clermont and Leblond (21). [1] Golgi phase: dot or patch-shaped SP-10-positive area was in the cytoplasm near the nucleus; [2] cap phase: crescent or half-moon-shaped SP-10-positive area was on the nucleus of round or elliptical cells in the cytoplasm; and [3] acrosome phase: crescent-shaped positive area at the end of a round or elliptical cell where the nucleus was closely attached to the

FIGURE 2

Light micrographs of immunostained (mature) spermatozoa, (immature) spermatids, and leukocytes in human semen smears. 1–6: the primary antibody used in the staining was a monoclonal antibody against the human intra-acrosomal antigen SP-10; 7, 8: the primary antibody used in the staining was a monoclonal antibody against the human leukocyte common antigen CD-45 located in the cell membrane. The immunopositive area is (dark) brown. G, Golgi phase round spermatid; C, cap phase round spermatid; E, early acrosome phase spermatid; L, late acrosome phase spermatid; S, spermatid symplasm; M, mature spermatozoa; W, leukocyte. Note that all the mature spermatozoa in micrographs 7 and 8 are immunonegative. Bar = 10  $\mu\text{m}$ .



cell boundary. Elongated cells, with or without a tail, were also regarded as acrosome phase spermatids provided their SP-10-positive area covered less than half of the head. Leukocytes were identified by their size, shape, and CD-45 immunoreactivity in which the whole cell was dark brown with weak immunoreaction over the nucleus (Figure 2). Immunonegative round cells were recorded separately.

### Cell Counting

Smears were observed using an oil immersion lens (100 $\times$ , Olympus, Tokyo, Japan, S Plan Apo, NA 1.40) on an Olympus BH-2 microscope. The image was captured with an F15 Panasonic video camera coupled to an Amiga 2000 computer using an Impact Vision 24 Professional video adaptor (Great Valley Products Inc., King of Prussia, PA). Fields were systematically sampled from a random start with a motorized stage. Eight rectangular frames (two rows), each with area 413  $\mu\text{m}^2$ , were generated by a software package (Grid V 1.2: Graffitidata, Silkeborg, Denmark) and superim-

posed on the video screen (final magnification 2,727 $\times$ ). All frames were used for the counting of immature spermatids, leukocytes, and other immunonegative round cells; however, the number of frames used for the counting of spermatozoa varied depending on the sperm count.

Spermatozoa were counted separately. Before counting the whole slide was scanned for immature spermatids or leukocytes. Six hundred forty frames were counted if no immature spermatids were observed; otherwise, at least 1,280 frames were counted. Sperm heads and other cells were counted according to the unbiased counting rule described by Gundersen (22).

The number of cells per unit area of smear were calculated and then the ratio between the numbers of immature spermatids, leukocytes, or other immunonegative round cells and the number of spermatozoa was calculated. The concentration of each cell type per milliliter of semen was deter-

TABLE 1

Semen analysis of control samples ( $n = 14$ )

Characteristic	Mean $\pm$ SEM (range)
Semen volume (mL)	3.0 $\pm$ 0.5 (2.0–4.8)
Sperm concentration (million/mL)	74 $\pm$ 14 (22–181)
Immature spermatid concentration (million/mL)	0.69 $\pm$ 0.20 (0–2.64)
No. per 1,000 spermatozoa	9.0 $\pm$ 1.9 (0–25.4)
Percentage in acrosomic phase	72 $\pm$ 8% (18–100%)
Leukocyte concentration (million/mL)	0.41 $\pm$ 0.25 (0–3.43)
No. per 1,000 spermatozoa	8.6 $\pm$ 5.8 (0–82.0)
Negative round cell concentration (million/mL)	0.25 $\pm$ 0.09 (0–1.19)

mined by multiplying the appropriate ratio by the sperm concentration in the original semen.

### Statistics

All data in text, figures, and tables are means  $\pm$  SEM. Statistical analysis was performed using SigmaStat V1.0 (Jandel Scientific Software, San Rafael, CA). Multiple comparisons of semen volume and the concentrations of sperm, leukocytes, and immature spermatids were performed. In the T + desogestrel group, sequential data from multiple time points was available in all men and one-way repeated measures analysis of variance (ANOVA) was used. In the case of the T + levonorgestrel study, different subgroups of the men provided samples at each time point and a standard ANOVA was used.

## RESULTS

Only spermatids (both round and elongated) were SP-10 immunoreactive in testicular sections (Figure 1). In semen samples containing spermatozoa ( $n = 39$ ), 70  $\pm$  3% of spermatozoa showed SP-10 immunoreactivity (Figure 2) and this proportion was not significantly different between groups at different time points or treatment regimens. The CD-45 immunostaining of leukocytes in semen smears is shown in Figure 2 (micrographs 7 and 8). When either primary antibody was omitted, no immunoreactivity was apparent (not shown).

### Baseline Semen Characteristics

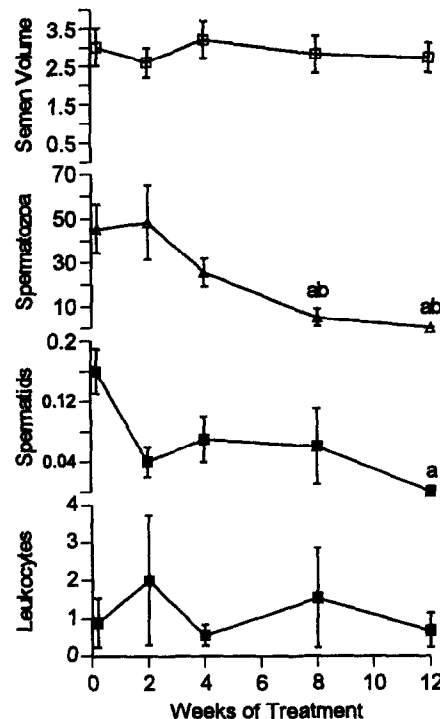
The semen analysis results from the 14 normal untreated men (five from control phase of T + desogestrel-treated group, and nine from untreated control group) have been combined in Table 1. Immature spermatids, leukocytes, and immunonegative round cells were observed in 13, 7, and 9 of the 14 samples, respectively, and, on average, there were 9.0, 8.6, and 2.5 of each per 1,000 spermatozoa, respectively (Table 1).

### Effects of Contraceptive Treatments

Changes in sperm, immature spermatid, and leukocyte concentrations during T + desogestrel are shown in Figure 3.

FIGURE 3

Semen volume (mL) and concentrations (million/mL of semen) of spermatozoa, immature spermatids, and leukocytes before (0 week), and 2, 4, 8, and 12 weeks after treatment with T plus desogestrel. (a)  $P < 0.05$  compared with pretreatment; (b)  $P < 0.05$  compared with 2 weeks of treatment.



Semen volume was unaltered by treatment. In the T + desogestrel-treated group, azoospermia was achieved in four of five patients; the fifth subject, receiving desogestrel 150  $\mu$ g daily plus T 50 mg/week, achieved a level of 0.1 million/mL.

In the T + levonorgestrel-treated group at the end of the suppressive phase, one subject was azoospermic, whereas the remaining three had sperm concentrations of 0.1–0.3 million/mL. During recovery (1–8 weeks after cessation of treatment) from T + levonorgestrel treatment ( $n = 6$ ), sperm concentrations remained partially suppressed. Five subjects had a sperm count between 0.1 and 2.8 million/mL and one had a count of 43.3 million, the average being 9.5  $\pm$  8.5 million/mL.

The concentration of immature spermatids decreased from 0.16 and 0.98 million/mL to undetectable levels after T + desogestrel and T + levonorgestrel treatments, respectively. One to eight weeks after the last T injection in the T + levonorgestrel group, the immature spermatid concentrations remained low (0.02 million/mL). Even during the initial suppression phase in T + desogestrel-treated group, when immature spermatids were still apparent, their number per 1,000 sperm did not increase.

The concentration of leukocytes and other immuno-

negative round cells were unchanged throughout T + desogestrel treatment. As a result, when the sperm concentration was reduced by ~90% after 8 weeks of T + desogestrel treatment, the number of leukocytes per 1,000 spermatozoa increased more than 50-fold (Fig. 3). No changes were seen in leukocytes and other immunonegative round cells after suppression and during recovery from T + levonorgestrel treatment.

## DISCUSSION

This study demonstrates that the number of immature spermatids in the ejaculate does not increase after contraceptive treatments using T in combination with either levonorgestrel or desogestrel. Using an immunocytochemical method for the identification of immature spermatids in seminal fluid (16), we found that the absolute numbers of immature spermatids decreased in parallel with the decrease in sperm concentration culminating in azoospermia or severe oligospermia and the disappearance of immature spermatid forms in most subjects. These data provide no support for the presence of spermatid sloughing as reported in the testosterone-treated rat (11). A less likely possibility is that spermatids were sloughed but underwent degeneration and reabsorption before ejaculation.

The immunocytochemical approach used in the present study has been used to detect immature germ cells in human semen and to label germ cells specifically at and beyond the immature spermatid stage (15, 16, 18). The use of an oil lens with a NA of 1.40 allowed good optical sectioning through the labeled cells, thus facilitating the differentiation of immature spermatids from other round cells. We observed that ~30% of mature sperm in the ejaculate failed to show SP-10 immunoreactivity in semen, possibly attributable to their having undergone acrosomal loss during processing. It is possible that some immature spermatids may have failed to show SP-10 reactivity because of acrosomal degeneration; however, it should be noted that the number of immunonegative round cells was low in control samples and decreased in response to contraceptive treatments. Thus, our conclusion that spermatid loss is not a key feature of these treatments remains unaltered.

An increase in the number of round (immature) spermatids in the semen has been reported during administration of 6-medroxy-progesterone acetate (12) or combinations of danazol and T (13). However, it is possible that leukocytes or other round cells were identified as spermatids in these studies because immunocytochemical methods were not available at that time to differentiate these cells. Numerous other studies using T alone or in combinations with progestins, have reported routine semen analysis findings; however, they have not specifically examined for any increases in spermatids or round cells (5, 6, 23–26).

It appears that, unlike the testosterone-treated rat (11), the sloughing of round spermatids is not common in the T-treated human. This difference in response between species may be explained by differences in FSH and testicular T responses to such treatment.

In the rat, testicular T levels decreased markedly after T treatment, whereas serum FSH levels remain normal (10, 27). Moderate reductions are seen in the numbers of spermatogonia and spermatocytes; however, the major lesion is the interruption of spermatid maturation with the resultant sloughing of round spermatids, which then appear in the epididymis (11).

In humans, and probably in other primates, FSH levels are suppressed by T (5, 6, 26, 28). On the other hand, in the hypophysectomized or GnRH-antagonist-treated monkey, relative to the rat, the reduction of testicular T levels appears to develop relatively slowly and is less severe (29, 30). In older men who are receiving a GnRH-agonist (GnRH-a) analog treatment for prostatic cancer, testicular T levels, although decreasing ~5% of control, remained at  $0.7 \times 10^{-7}$  mol/L (~20 ng/g) (31), a concentration that is adequate to support aspects of spermatogenesis in several animal species (32–34).

The primary spermatogenic lesion seen in primates after gonadotropin withdrawal appears to be in spermatogonial maturation (35); a similar lesion has been suggested in humans, although quantitative data are lacking (24). We speculate that the suppression of FSH in T-treated men primarily inhibits spermatogonial division, which results in the progressive disappearance of spermatocytes, spermatids, and sperm. A specific lesion in spermatid maturation leading to spermatid sloughing is not a key feature of this process as evidenced by the study of germ cells in the ejaculate, perhaps attributable to the persistence of T action on spermiogenesis. Further studies involving quantitative analysis of spermatogenic dynamics in the primate testis during contraceptive regimens are needed to test this hypothesis.

## References

1. Heller CG, Laidlaw WM, Harvey HT, Nelson WO. Effects of progestational compounds on the reproductive processes of the human male. *Ann NY Acad Sci* 1958;71:649–65.
2. Heller CG, Nelson WO, Hill IB, Henderson E, Maddock WO, Jungck EC, et al. Improvement in spermatogenesis following depression of the human testis with testosterone. *Fertil Steril* 1950;1:415–22.
3. Cummings DE, Bremner WJ. Prospects for new hormonal contraceptives. *Endocrinol Metab Clin North Am* 1994;23:893–922.
4. Cummings DE, Bremner WJ. Male contraception: Ideas for the future. In: CW Bardin, editor. *Current therapy in endocrinology and metabolism*. 6th ed, New York: Wiley-Liss, 1997:300–4.
5. WHO Task Force on Methods for the Regulation of Male Fertility. Contraceptive efficacy of testosterone-induced azoospermia in normal men. *Lancet* 1990;336:955–9.
6. Handelsman DJ, Farley TM, Peregoudov A, Waites GMH, WHO Task Force on Methods for the Regulation of Male Fertility. Factors in nonuniform induction of azoospermia by testosterone enanthate in normal men. *Fertil Steril* 1995;63:125–33.
7. WHO Task Force on Methods for the Regulation of Male Fertility. Contraceptive efficacy of testosterone-induced azoospermia and oligospermia in normal men. *Fertil Steril* 1996;65:821–9.
8. Anderson RA, Wu FCW. Comparison between testosterone enanthate-induced azoospermia and oligospermia in a male contraceptive study.

- II. Pharmacokinetics of once weekly administration of testosterone enanthate. *J Clin Endocrinol Metab* 1996;81:896–901.
9. Bebb R, Anawalt B, Christensen R, Paulsen CA, Bremner WJ, Matsumoto AM. Combination testosterone and levonorgestrel induces more rapid and effective suppression of spermatogenesis than testosterone alone: a promising male contraceptive approach. *J Clin Endocrinol Metab* 1996;81:757–62.
  10. O'Donnell L, McLachlan RI, Wreford NG, Robertson DM. Testosterone promotes the conversion of round spermatids between stages VII and VIII of the rat spermatogenic cycle. *Endocrinology* 1994;135:2608–14.
  11. O'Donnell L, McLachlan RI, Wreford NG, de Kretser DM, Robertson DM. Testosterone withdrawal promotes stage-specific detachment of round spermatids from the rat seminiferous epithelium. *Biol Reprod* 1996;55:895–901.
  12. MacLeod J. The significance of deviations in human sperm morphology. In: Rosenberg E, Paulsen CA, editors. *The human testis*. New York: Plenum Press, 1970:481–94.
  13. Ulstein M, Netto N, Leonard J, Paulsen CA. Changes in sperm morphology in normal men treated with danazol and testosterone. *Contraception* 1975;12:437–44.
  14. Wolff H, Anderson DJ. Immunohistologic characterisation and quantitation of leukocytes subpopulations in human semen. *Fertil Steril* 1988;49:497–504.
  15. Herr JC, Wright RM, John E, Klotz K, Homyk M, Foster J, et al. Monoclonal antibody MHS-10 and its cognate intra-acrosomal antigen SP-10. In: Gamete interaction: Prospects for immunocontraception. New York: Wiley-Liss, 1990:13–36.
  16. Homyk M, Anderson DJ, Wolff H, Herr JC. Differential diagnosis of immature germ cells in semen utilising monoclonal antibody MHS-10 to the intra-acrosomal antigen SP-10. *Fertil Steril* 1990;53:323–30.
  17. Foster JA, Herr JC. Interactions of human acrosomal protein SP-10 with the acrosomal membranes. *Biol Reprod* 1992;46:981–90.
  18. Kurth BE, Klotz K, Flickinger CJ, Herr JC. Localisation of sperm antigen SP-10 during the six stages of the cycle of the seminiferous epithelium in man. *Biol Reprod* 1991;44:814–21.
  19. World Health Organization. Laboratory manual for the examination of human semen and sperm–cervical mucus interaction. 2nd ed. Cambridge: The Press Syndicate of the University of Cambridge, 1992:3–27.
  20. Robinson G, Ellis IO, MacLennan KA. Immunocytochemistry. In: Bancroft JD, Stevens A, Tuner DR, editors. *Theory and practice of histological techniques*. Edinburgh: Churchill Livingstone, 1990:413–36.
  21. Clermont Y, Leblond CP. Spermiogenesis of man, monkey, ram and other mammals as shown by the “periodic acid-schiff” technique. *Am J Anat* 1955;96:229–53.
  22. Gundersen HJG. Notes on the estimation of the numerical density of arbitrary profiles: the edge effect. *J Microsc* 1977;111:219–23.
  23. Schearer SB, Alvarez-Sanchez F, Anselmo J, Brenner P, Coutinho E, Latham-Faundes A, et al. Hormonal contraception for men. *Int J Androl* 1978;2(Supp):680–712.
  24. Rowley MJ, Heller CG. Summary of studies utilising androgens in the normal human male. In: Patanelli DJ, editor. *Hormonal control of male fertility*. US Department of Health, Education and Welfare, Publication No (NIH) 78-1097, 1978:145–166.
  25. Swerdloff RS, Wang C, Bhasin S. Male contraception: 1988 and beyond. In: Burger H, de Kretser DM, editors. *The testis*. New York: Raven Press, 1989:547–68.
  26. Wallace EM, Gow SM, Wu FCW. Comparison between testosterone enanthate-induced azoospermia and oligozoospermia in a male contraceptive study. I. Plasma luteinizing hormone, follicle stimulating hormone, testosterone, estradiol, and inhibin concentrations. *J Clin Endocrinol Metab* 1993;77:290–3.
  27. McLachlan RI, Wreford NG, Tsonis C, de Kretser DM, Robertson DM. Testosterone effects on spermatogenesis in the gonadotropin-releasing-hormone-immunised rat. *Biol Reprod* 1994;50:271–80.
  28. Matsumoto AM. Effects of chronic testosterone administration in normal men: safety and efficacy of high dosage testosterone and parallel dose-dependent suppression of luteinising hormone, follicle-stimulating hormone and sperm production. *J Clin Endocrinol Metab* 1990;70:282–7.
  29. Marshall GR, Jockenhövel F, Lüdecke D, Nieschlag E. Maintenance of complete but quantitatively reduced spermatogenesis in hypophysectomized monkeys by testosterone alone. *Acta Endocrinologica* 1986;113:424–31.
  30. Weinbauer GF, Gockeler E, Nieschlag E. Testosterone prevents complete suppression of spermatogenesis in the gonadotropin-releasing hormone antagonist-treated non human primate (*Macaca fascicularis*). *J Clin Endocrinol Metab* 1988;67:284–90.
  31. Huhtaniemi I, Nikula H, Parvinen M, Rannikko S. Pituitary-testicular function of prostatic cancer patients during treatment with a gonadotropin-releasing hormone agonist analog. II. *Endocrinology and histology of the testis*. *J Androl* 1987;8:363–73.
  32. Desjardins C, Ewing LL, Irby DC. Response of the rabbit seminiferous epithelium to testosterone administered via polydimethyl siloxane capsules. *Endocrinology* 1973;93:450–60.
  33. Cunningham GR, Huckins C. Persistence of complete spermatogenesis in the presence of low intratesticular concentrations of testosterone. *Endocrinology* 1979;105:177–86.
  34. Ewing LL, Zirkin BR, Cochran RC, Kromann N, Peters C, Ruiz-Bravo N. Testosterone secretion by rat, rabbit, guinea pig, dog and hamster testes perfused in vitro: correlation with Leydig cell mass. *Endocrinology* 1979;105:1135–42.
  35. Weinbauer GF, Behre HM, Fingscheidt U, Nieschlag E. Human follicle-stimulating hormone exerts a stimulatory effect on spermatogenesis, testicular size, and serum inhibin levels in the gonadotropin-releasing hormone antagonist-treated non-human primate (*Macaca fascicularis*). *Endocrinology* 1991;129:1831–9.