

Antegonial notching and the pattern of vertical facial growth

Maggie Wang

A thesis

submitted in partial fulfillment of the  
requirements for the degree of

Master of Science in Dentistry

University of Washington

2012

Committee:

David Turpin  
Sue Herring  
Greg Huang  
Curtis Chen  
Barbara Sheller

Program Authorized to Offer Degree:  
School of Dentistry, Department of Orthodontics

**University of Washington**

**Abstract**

**Antegonial notching and the pattern of vertical facial growth**

Maggie Wang

Chairperson of the Supervisory Committee:  
Moore-Riedel Professor, David L. Turpin

School of Dentistry, Department of Orthodontics

**Introduction:** This study evaluated whether panoramic radiographs can provide an adequate estimate of antegonial notch depth and compared development of the antegonial notch with vertical growth in various patient groups.

**Methods:** Longitudinal growth-period cephalograms were collected for 43 open bite (OB), 61 Pierre Robin sequence (PRS), 13 idiopathic condylar resorption (ICR), and 104 matched controls, along with 35 pairs of panoramic and cephalometric radiographs. Notch depth, mandibular plane angle and vertical facial dimensions were measured.

**Results:** Antegonial notch depth taken from panoramic radiographs was well correlated with cephalometric measurements but underestimated the value by 0.56mm. At T1, notch depth was already greater in patient groups than in controls, but except for the ICR group, did not change during growth, nor did notch depth predict vertical growth patterns. The ICR group was unique in having greater notch depth than OB even at T1, in showing poor growth of posterior facial height, and in the increasing mandibular plane angle. In controls, antegonial notch depth was positively correlated with vertical dimensions and mandibular plane angle.

**Conclusions:** Panoramic radiographs are an adequate substitute for cephalograms for estimating antegonial notch depth. Except in ICR, notch depth is established early and maintained throughout the growth period, and therefore is not a good predictor of future vertical facial growth. An unusually deep notch at T1 may indicate that a patient is at risk for ICR.

## Table of Contents

<b>List of Figures</b> .....	ii
<b>List of Tables</b> .....	iii
<b>Introduction</b> .....	1
<b>Materials and Methods</b> .....	2
<b>Results</b> .....	6
<b>Discussion</b> .....	10
<b>Conclusions</b> .....	18
<b>References</b> .....	25
<b>Appendix</b> .....	28

## List of Figures

### Figure Number

1. Antegonial notch.....	19
2. Landmarks and measurements.....	19
3. Antegonial notch measurement on panoramic images.....	19
4. Antegonial notch measurement on cephalometric images.....	20
5. Scatter plot of panoramic and cephalometric means of antegonial notch depth.....	20

## List of Tables

### Table Number

1. Definition of parameters identified in radiographs .....	21
2. Descriptive data for panoramic and cephalometric comparison of antegonial notch depth .....	22
3. Descriptive data for patient and their control groups in gender, age, and time span .....	22
4. Comparison between patient and their control groups for cephalometric means, changes in variables from T1 to T2 by subtracting measurements at T1 from measurements at T2 in patient and their control groups .....	23
5. Correlation between changes in antegonial notch depth, lower anterior facial height, posterior facial height, and mandibular plane angle in patient and their control groups... .....	24
6. Correlation between antegonial notch depth at T1 and the changes in other variables.....	24
7. Correlation between antegonial notch depth and other variables at T2 in different groups .....	24

## **Introduction**

The origin of antegonial notching has long been an interesting topic for those studying growth and development of the mandible. In recent years, the mandibular antegonial notch, observed as a concavity in the inferior border of the mandible anterior to the gonial angle (Figure 1), has been associated with different facial characteristics. Prominent antegonial notching has been seen with acquired and congenital abnormalities of the mandible [Becker et al. 1976]. Although the development of the antegonial notch has never been fully understood, it has been observed in Bjork's study that mandibles with a backward growth pattern exhibited a pattern of surface deposition under the mandibular angle, leading to concavity on the inferior border of the mandible i.e. antegonial notch [1968].

The current study evaluates the correlation between panoramic and cephalometric radiographs in measuring antegonial notch depth for research purposes. Lateral cephalograms are mostly used in orthodontic practice to evaluate a patient's pattern of growth as changes occur in anterior-posterior skeletal and dentoalveolar relationships prior to and after orthodontic treatment. Most patients do not have consecutive cephalometric radiographs taken unless they are planning to receive orthodontic treatment in the future. Panoramic radiographs, on the other hand, are frequently taken throughout the life of a patient. Although compared to cephalograms, panoramic radiographs clearly differentiate left and right, due to the widely known magnification and distortion on the panoramic radiographs, the reliability of linear measurements are always debatable. The present study directly compares the two types of radiographs in the hope of developing a formula for predicting cephalometric antegonial notch depth using panoramic values.

In addition, the present study addresses vertical growth of the face, especially comparing posterior facial height (mandibular ramus) with anterior facial height in terms of their size, their increases over time, and their relationship to each other (mandibular plane angle). We expected notch depth to be associated with greater anterior than posterior vertical dimensions and growth, at least in extreme patient groups such as those with anterior open bite. This study compares development of the antegonial notch in specific patient groups throughout their growth. These groups are: normal occlusion (class I), anterior open-bite, Pierre Robin sequence, and idiopathic condylar resorption. This comparison, undertaken here for the first time, will assess not only differences in notch depth among these patient groups, but also whether notch depth predicts vertical growth in any of the groups.

Although much is known about the growth and development of the mandible, its later modeling is still not completely understood. This study will provide insight into morphological changes that occur at the antegonial region in special patient populations. Moreover, the data gathered will assess whether, and for which patients, this feature can act as a predictor of mandibular growth.

## **Materials and Methods**

This thesis was designed as a two-part project: a cross-sectional study and a retrospective longitudinal study, utilizing records from the University of Washington Orthodontic Department, Seattle Children's Hospital Dental Department, and the Toronto Sick Children's Hospital Orthodontic Department. Prior Institutional Review Board was approved by each facility.

Sample selection was based upon the following inclusion criteria: (1) consecutive radiographs taken at any age during the growth period, including the earliest available radiograph (T1), and the last radiograph at the end of growth period (T2). (2) Panoramic and lateral cephalometric radiographs of diagnostic quality, (3) cephalometric radiographs with posterior teeth in occlusion, (4) all radiographs prior to orthognathic surgery. Orthodontic treatments including fixed or removable functional appliances used during the observation period were not an exclusion criterion.

#### *Panoramic vs. Cephalometric radiographs sample*

Matching panoramic and cephalometric radiographs taken at the same time were obtained from the available longitudinal samples. All images were hard copies. Antegonial notch depth was measured. If the mandibular borders were superimposed on the cephalometric radiographs, one value was taken. If both left and right mandibular borders could be seen clearly on the cephalometric radiographs, the bigger value of the two was taken.

#### *Control sample*

The control sample was defined as patients with non-treated Class I malocclusion. All the control cases were provided by the American Association of Orthodontists Foundation (AAOF) online database. Control cases were selected to match the open bite, Pierre Robin, and ICR cases in age and gender. Records from the following collections were used: Burlington Growth, Denver Growth, Forsyth Twin, Iowa Growth, Michigan Growth, Oregon Growth, UOP Matthews Growth, and the WSU Fels Longitudinal. High definition digital images in the original (.tif) format were measured.

### *Open bite sample*

Patients were selected from a sample used in a prior study at the University of Washington (Huang, 1989). All of these patients used a crib to modify the tongue and/or thumb habit, and most were followed by treatment with full fixed orthodontic appliances. All radiographs were hard copies.

### *Pierre Robin sample*

Seattle Children's Hospital Dental Department and the Toronto Sick Children's Hospital Orthodontic Department provided cases for the Pierre Robin group. All patient records on file matching our inclusion criteria were screened. All the radiographs were hard copies.

### *Idiopathic condylar resorption sample*

Using the 2012 American Association of Orthodontists member directory, an email was sent to 50 private orthodontists who practice in the Puget Sound area, requesting their contribution of records of idiopathic condylar resorption patients. They were informed of the nature of the study and asked to submit longitudinal cephalometric and panoramic radiographs. Digital and hardcopy images were received.

### *Data collection and measurement*

A single investigator (M.W.) traced all hardcopy radiographs with a 0.50-mm H lead mechanical pencil onto acetate films. Skeletal landmarks defined in Table I were used for measurement. The images were then scanned with a millimeter ruler and digitized using an Epson 800 scanner. Image calibration gave a value of 150 pixels per millimeter. The images

were stored as TIF images on a Macintosh computer. Figure 2 illustrates the cephalometric points from which measurements were made. Figures 3 and 4 depict antegonial notch depth measured as the distance along a perpendicular line from the deepest point of notch concavity to a tangent through the two points of greatest convexity on the inferior border of the mandible.

Adobe® Photoshop® CS4 Extended Version 11.0.2 was used for landmark identification for digital records and measuring all samples. Linear measurements were calibrated by the software's auto-recognition of digital images' dots per inch (DPI), and the correct conversion rate to millimeter was given. Data were entered into an Excel (Microsoft; 2007 version) spreadsheet and then exported into SPSS (IBM; Version 20) for statistical analysis. Descriptive statistics for all patient and control samples were calculated for all variables. T-tests were used to assess differences in changes in antegonial notch, lower anterior facial height, posterior facial height, and mandibular plane angle between groups and their controls. Considering some of the small sample sizes, non-parametric statistics such as Wilcoxon rank sum tests were performed, giving the same results as the student T-tests. Therefore, only the results from the student T-tests are reported. Linear regression analysis was done to estimate the correlation between changes in antegonial notch depth and other anatomical measurements. Linear regression was also used to determine the correlation between antegonial notch depth measured on cephalometric and panoramic radiographs. For all tests, significance was established at the  $p < 0.05$  level.

To test the reliability, 40 cephalometric radiographs randomly selected from the Open Bite sample and repeated measurements were performed by the same examiner twelve months after the initial measurement. Dahlberg's formula was used to determine the error: Error of method<sup>2</sup> =  $\sum d^2 / 2n$ , where  $d$  is the difference between two measurements and  $n$  is the number of double determinations. The errors for antegonial notch depth, lower anterior facial height,

posterior facial height, and the mandibular plane angle were 0.093mm, 0.961mm, 1.511mm, and 1.347 degrees. Correlation analysis between the repeated measurements showed r's equal to 0.99, 0.98, 0.96, and 0.94.

## **Results**

### *Antegonial notch depth measurement on panoramic vs. cephalometric radiographs*

Thirty five sets of matching panoramic and cephalometric radiographs were obtained from the available longitudinal sample sets (Table 2). Strong correlation was found between measurements taken from means of left and right sides of panoramic and cephalometric radiographs ( $r=0.79$ ,  $p<0.001$ , Figure 5). The least squares regression equation was calculated with a slope of 0.82 and intercept of 1.15. According to Hofman (1988), the equation of reduced major axis (RMA) is more appropriate than the standard least squares regression when the independent variable is measured with error, such as in our study. The RMA equation can be derived from the least squares regression by using the Pearson's correlation coefficient. The RMA slope equals the slope of the least squares regression divided by the Pearson's coefficient. The RMA intercept can be obtained by plugging in the means of the data sets as x and y components of the equation. Therefore, the RMA equation is the mean cephalometric value =  $1.04 \times \text{mean panoramic value} + 0.56$ . Similar results were found for the correlation between the largest values of either side of the antegonial notch on the radiographs.

### *Open bite vs. control*

Forty-three open bite patient records (29 girls and 14 boys) from a sample used in a prior study at the University of Washington (Huang, 1989) met the criteria. Descriptive results are

presented in Tables 4. The open bite group (average age at T1, 10.08 years) was matched to a control group (average age at T1, 10.29 years). The mean time interval examined was 6.52 years for the open bite group and 5.24 years for the control group. There were significant differences in the antegonial notch depth and mandibular plane angles between the groups at T1. In the open bite group, at T1, the mean antegonial notch depth was 0.45mm deeper ( $p<0.05$ ) and the mean mandibular plane angle was 2.7 degrees higher ( $p<0.05$ ) than those in the control group. The differences between the groups continued at T2, with no significant difference between T1 and T2 within each group. All measurements increased during the observation period in both groups as expected during growth.

Linear correlation analysis (Tables 5) showed that in neither the open bite sample nor the control sample was increase in antegonial notch depth correlated with any other vertical measurements.

#### *Pierre Robin vs. control*

Twenty-six Pierre Robin cases (13 girls and 13 boys) were collected from the Seattle Children's Hospital Dental Department and the thirty-five cases (24 girls and 11 boys) were collected from the Toronto Sick Children's Hospital Orthodontic Department. Descriptive data are presented in Tables 4. The Pierre Robin group (average age at T1, 6.82 years) and the control group (average age at T1, 6.76 years) had mean time intervals examined of 9.28 years for the Pierre Robin group and 8.69 years for controls. At T1, all measurements were significantly different between the groups, except the lower anterior facial height. In the Pierre Robin group, at T1, the mean antegonial notch depth was 0.97mm deeper ( $p<0.001$ ) and the mean mandibular plane angle was 9.4 degrees higher ( $p<0.001$ ) than those in the control group. The differences of

antegonial notching between the groups continued at T2, with no significant difference between T1 and T2 within either group. All measurements increased in both groups, except mandibular plane angle, as expected during growth.

Linear regression analysis (Table 5) showed that in the Pierre Robin, increase in antegonial notch depth was not correlated with any other measurements. In the control group, however increase in antegonial notch was correlated with increases in lower anterior facial height and posterior facial height ( $r=0.36$  for both,  $p<0.01$ ).

### *Idiopathic condylar resorption*

Due to the rare nature and random occurrence of idiopathic condylar resorption, it was not expected that an adequate sample size to detect differences with respect to this condition would be achieved. The descriptive statistics of a sample of the 13 cases (all females) collected can be found in Table 4. The average age at T1 was 10.85 and at T2 was 16.9 years old. It is unknown whether the radiographs at T1 were taken prior or during the onset of idiopathic condylar resorption, or whether the progression of the condition ceased prior to or after T2. All the patients were reported to show clinical signs of the condition prior to or at the T2 time point. Therefore it was assumed that most if not all subjects had progression of the condition during the observation period. Control cases were chosen by matching 26 females from the controls used for the Open Bite group, because they were close to the ICR group in age.

At T1, there were insignificant differences between the two groups in lower anterior facial height and posterior facial height. In the ICR group, lower anterior facial height increased an average of 6.7mm with only 1.1mm increase of posterior facial height. Posterior facial height increased four times more in the untreated control group than in the ICR group. Average

antegonial notch depth in ICR group, already greater than the controls at T1, increased more during growth. Linear regression (Table 5) showed that increase in antegonial notch depth was positively correlated with the increase in lower anterior facial height and mandibular plane angle.

#### *Idiopathic condylar resorption vs. open bite*

To compare open bite and the ICR groups, all 29 females from the open bite group were used to compare with the 13 females in the ICR group. Descriptive data can be found in Table 4. At T1, only antegonial notch depth was significantly different between the groups and other measurements were similar statistically. All measurements increased during the observation period. The increase in posterior facial height in the open bite group was almost four times of that in the ICR group. The increase in mandibular plane angle in ICR was almost five times of that in the open bite group. Antegonial notch and lower anterior facial height changes were not significantly different between the two groups.

#### *Can antegonial notch depth predict mandibular growth?*

Linear regression analysis was performed to evaluate the correlation between the antegonial notch depth at T1 in each group and the changes in other measurements (Table 6). No significant correlation was found in any group. However, it is notable that antegonial notch depth at T1 tended to be positively correlated with posterior facial height growth in control and open bite patients, but negatively correlated with posterior facial height growth in PRS and ICR groups.

*Is a deep antegonial notch correlated with a steep mandibular plane angle?*

In an effort to take growth out of the equation, correlation between antegonial notch depth and other measurements was calculated at T2, presumably when growth was complete in all groups (Table 7). In the control group, which had the biggest sample size, increase in antegonial notch depth was correlated with increase in lower anterior facial height ( $r=0.36$ ,  $p<0.01$ ), posterior facial height ( $r=0.34$ ,  $p<0.01$ ), and mandibular plane angle ( $r=0.18$ ,  $p<0.05$ ). This pattern appeared to be similar in open bite and Pierre Robin groups, but coefficients were lower and not significant. However, the trend was different in the ICR group and almost no correlation was found between antegonial notch depth and lower anterior facial height and the mandibular plane angle.

## **Discussion**

*Antegonial notch depth measurement on panoramic vs. cephalometric radiographs*

Ghosh, et al. concluded that the use of a panoramic radiograph for determination of the antegonial depth could be considered reliable [2010]. Their results showed that minor antero-posterior shifts and tilts of the mandible are associated with a variation of less than 2% for measurements taken in the vertical plane [Dutra et al., 2004 and Xie et al., 1996].

Our study was the first to directly compare the two types of radiographs in measuring antegonial notch depth. Our results indicate that panoramic radiographs are adequate predictors of antegonial notch depth if cephalometric radiographs are not available. Although cephalometric radiographs are known to have less distortion in vertical linear measurements, clinically, panoramic radiographs are taken much more frequently throughout a patient's life time. A relatively high correlation coefficient (0.82) between panoramic and matching cephalometric

radiographs indicates that panoramic radiographs reflect the antegonial notch depth relatively well. The resulting RMA equation (Ceph notch depth =  $1.04 \times \text{Pan notch depth} + 0.56$ ) shows that on average, the panoramic radiograph underestimates the notch depth by about 0.6mm.

#### *Antegonial notch and vertical mandibular dimensions in specific patient groups*

The present study represents the most systematic attempt to date to assess specific patient populations, i.e. open bite, Pierre Robin sequence, and idiopathic condylar resorption patients, which often show significant antegonial notching and related facial characteristics.

At T1 the open bite patients had significantly deeper antegonial notch depth and steeper mandibular plane angle. At T2, those two measurements remained significantly different between the two groups. Antegonial notch appears to be established before 10 years of age and most likely is maintained during growth period. Although we have no evidence, we suspect that most of our open bite subjects had a combination of dental and skeletal open bite, with a tongue habit. Limited orthodontic treatment with a tongue crib reduced their open bite [Huang 1989], but evidently did not change the skeletal pattern. The unique vertical facial characteristics did not revert to resemble those in the untreated control group. During the observation period, all the measurements changed in similar amounts in both groups.

Studies have shown that anterior open bite may be associated with internal derangement (ID or disc displacement) of the TMJ [Byun et al. 2005 and Gidarakou et al. 2003]. ID is defined as an abnormal relationship of the articular disc to the condyle, fossa, and articular eminence. The more severe the abnormality of the TMJ, the more pronounced the dentofacial characteristics, such as a decrease in posterior facial height, decrease in ramus height, and backward rotation of the mandible [Gidarakou et al. 2003]. For example, the pattern is more

severe in patients with disc displacement without reduction than those with reduction [Byun et al. 2005]. It is reasonable to suspect that our open bite sample included subjects with undiagnosed ID. However, this is unlikely to characterize most of the sample, because the age changes in the cephalometric measurements did not deviate from the control sample.

Severe antegonial notching characterizes Pierre Robin sequence patients, although mandibular morphology varies depending on the presence and types of syndromes associated. Whether it is syndromic or non-syndromic, PRS often involves condylar growth programs [Pirttiniemi et al. 2009]. The PRS mandible is characterized by a large antegonial notching that is related to the severe retrognathia and a backward rotation of the mandible [Hermann et al., 2003]. It is of clinical importance that the mandibular growth of a specific PRS patient can be predicted so that a proper treatment plan can be formulated at the right time. One of the ongoing interests in the area is to find out whether a specific patient will show catch-up mandibular growth, compensating at least in part for the skeletal discrepancy. Our study did not directly investigate this question as we only focused on the vertical dimension of facial growth. However we observed that the PRS and control groups showed similar changes in all measurements during the observation period. Although born with congenital deformities and most likely condylar growth problems, PRS subjects appear to have a normal vertical growth pattern. All measurements except for anterior facial height were significantly different at both time points. As in the open bite and the control groups, antegonial notch depth was established early (prior to 6.7 years old) and most likely will be maintained during growth. Clinicians need to be aware that PRS patients are most likely to maintain their distinct facial features without surgical treatment. Further study needs to be done to examine whether horizontal mandibular growth can “catch up” with the maxillary growth in PRS individuals. Our PRS group probably included only milder cases

because patients who had mandibular distraction or orthognathic surgeries were excluded. Our PRS group also included a mix of syndromic and non-syndromic PRS with unknown TMJ and condylar problems. It is possible that more severe cases or a more homogeneous sample would have yielded a different result.

Idiopathic condylar resorption (ICR) is an increasingly used term, representing acquired disease or trauma with associated condylar disorders. It describes the condition of unknown origin of partial resorption of the mandibular condyles, causing a loss of condylar height and alteration of the occlusion and facial characteristics to different degrees depending on the severity of the resorption. ICR has been shown to affect mostly females aged 15 to 35 years, with higher frequency in teenage girls during the pubertal growth spurt [Posnick and Fantuzzo 2007]. ICR generally causes progressive condylar resorption followed by stabilization without further resorption. ICR frequently occurs spontaneously without an obvious external trigger. ICR patients present a unique and significant challenge to the orthodontist. It can develop prior to, during, or post orthodontic treatment. Frequently, ICR patients present with gradually increasing anterior open bite, Angle Class II occlusion, increased overjet, and retrognathic mandible, and backward inclination of the mandible, and a large antegonial notching [Kreiborg et al 1990]. It is important for orthodontists to recognize the early signs of ICR by observing changes in occlusion and facial profile.

Although not classified as a form of internal derangement, the disharmony in the TMJ complex is much more severe in the ICR patients. One of the challenges we encountered was in collecting a uniform sample, due to the rare and mixed nature of this poorly understood condition. ICR can be insidious and may only be suspected when signs such as increased anterior open bite present in the orthodontic offices. After ruling out the common known etiologies such

juvenile rheumatoid arthritis, orthodontists often utilize radiographic images determine whether the condition has stabilized. Sometimes the treatment decision is solely based on consecutive cephalometric radiographs, without direct images of the joint. It is crucial that the orthodontists understand and recognize the cephalometric changes associated with progressive ICR.

Like the open bite cases, the ICR subjects already demonstrated significant deviation from the controls at T1 with deeper antegonial notch depth and steeper mandibular plane angle. During the observation period, the ICR group changed significantly more than the controls in all dimension, except lower anterior facial height. The mandibular plane angle increased an average of 5 degrees during growth, versus the decrease in all other groups. This observation coincides with the hypothesis that the mandible opened in a clockwise fashion. Importantly, linear correlation analysis showed that increase in antegonial notching in ICR was correlated with increases in lower anterior facial height and mandibular plane angle.

Although clinically open bite and ICR patients often present with similar facial and dental characteristics such as steeper mandibular plane angle and open bite, drastic differences in growth patterns can be expected. In the ICR group, posterior facial height only increased one quarter as much as in the open bite group. The 5 ° increase of mandibular plane angle in ICR indicates significant clockwise rotation of the mandible with bite opening effect, whereas no change was observed in open bite sample. Therefore, we directly compared the all-female ICR group with all the females of the open bite group (Table4). Interestingly, antegonial notch depth was the only measurement to show a significant difference at T1, averaging 3mm in ICR and 2mm in open bite. Further differences developed over time. Therefore, the best indication of whether patients presenting with open bite and long face presentation will have a normal growth pattern as in the open bite group, or will worsen discrepancies as in the ICR group is a very deep

antegonial notch at T1. Incipient TMJ problems may be recognized early by comparing serial cephalometric measurements.

*Can antegonial notch depth predict vertical facial growth?*

This study also investigated whether antegonial notch depth at young age could be used as a predictor for the amount and pattern of vertical mandibular growth. Linear analysis failed to show correlation between antegonial notch depth at T1 and the changes in other dimensions over the observation period in any group. Thus, despite the clinical opinions many orthodontists might hold, antegonial notching depth is not a predictor of future vertical growth and rotation of the mandible, even in patient groups that commonly present with extreme antegonial notching. This is consistent with Singer et al. [1987] and Kolodziej et al. [2002], who concluded that antegonial notching cannot provide sufficient indication of future facial growth either in the normal population or in patients with antegonial notch depth greater than 3mm.

*Is deep antegonial notch correlated with steep mandibular plane angle?*

Removing growth from the discussion, we also asked whether anatomically a deep antegonial notch was related to facial features such as increased lower anterior facial height, decreased posterior facial height, and steep mandibular plane angle. Correlation analysis on individual groups at T2, when growth was assumed to be complete, showed that in the control group deep antegonial notch depth was correlated with increased lower anterior facial height, posterior facial height, and mandibular plane angle. This pattern appeared to be similar in open bite and Pierre Robin groups, although coefficients were lower and not statistically significant. However, the trend was different in the ICR group, where correlations were between antegonial

notch depth and lower anterior facial height, and between antegonial notch depth and mandibular plane angle were 0. Although further studies need to be done, we suspect that in the normal population antegonial notch depth for is associated with vertical growth in general. Although deviated from the norms at all times, open bite and PRS patients most likely follow same pattern. However, vertical growth is less in ICR, a group of patients with acquired disease of the TMJ.

#### *Development of the antegonial notch*

Previous studies have linked development of the antegonial notch with a backward mandibular rotation and vertical growth pattern. The current study obviously cannot establish a causal relationship between antegonial notch and the direction of mandibular growth. Our results are generally consistent with the theory, although the strength of the relationship was weak. In the control, open bite, and Pierre Robin groups, antegonial depth was essentially constant during the adolescent growth spurt as the mandibular plane angle decreased significantly, exhibiting a closing growth pattern. The ICR group was the only one to show increase in antegonial depth and also demonstrated a significant increased in mandibular plane angle, indicating bite opening. It seems clear that these two unusual changes were associated with the deepening of the notch and opening of the bite, accompanying continued normal anterior vertical growth while posterior vertical growth ceased.

One possibility of antegonial notch development is that the body of the mandible may rotate downward around a center of resistance near the antegonial notch, in an effort to maintain a normal anterior facial height and volume. As the mandibular body flexes downward, a notch develops on the surface near the center of resistance. One would expect the gonial angle to increase as the anterior open bite and mandibular plane angle increase. It may suggest antegonial

notch develop due to mandibular flexure that causes gonial angle to increase. To test this hypothesis, the examiner measured the changes in gonial angle in the ICR and its control group. At T1, the mean gonial angle in ICR group is 129.6 degrees, and 128.5 degrees in the controls. At T2, it is 128 degrees in the ICR group and 127.1 degrees in the controls. Both groups showed comparable decrease in gonial angle with age, which is supported by previous literature. The student T tests showed insignificant difference between the two groups in gonial angles at T1 and T2. In addition, neither positive nor negative correlation was found between the increase in antegonial notch depth and the decrease in gonial angle in either group. Therefore, our result does not support that antegonial notch development is associated with mandibular flexure at the gonial angle.

### *Limitations*

A significant limitation in this study was the inability to standardize the radiographic measurements or to blind the examiner to their identity. The patient records were provided by multiple educational facilities and private orthodontic offices. Radiographs included hardcopy and digital images and were taken at different period of time on different x-ray machines. The inherent errors in magnification created by the machines could not be calibrated. Distortion and magnification created by patient's head positioning errors were not adjusted. Previous studies have shown that the projection errors in length measurements are minor in cephalometric radiography. Rotation of  $\pm 5^\circ$  from the ideal head position usually results in errors that are less than 1%. Such error is usually insignificant and will in most instances be concealed by other errors, such as landmark identification and registration errors [Ahlqvist et al., 1986].

One thing worth noting was that the control samples from AAOF might not be representative of the general class I untreated population. The mandibular plane angle at T1 averaged 36°. According to Steiner, the average reading of mandibular plane angle related to the anterior cranial base (SN) is 32 degrees [Jacobson and Jacobson 2006]. Because the control samples presented with higher mandibular plane angles, other vertical mandibular measurements and the growth pattern may also have deviated from the general population.

### **Conclusions**

1. The panoramic radiograph is an adequate tool for estimating antegonial notch depth.
2. Antegonial notch is established early in age and maintained throughout the growth period, except in the idiopathic condylar resorption group.
3. In a growing population, antegonial notch depth at a mixed dentition age (6.5-10 years old) is not a good predictor for the amount of future vertical mandibular growth, although a particularly deep notch may suggest that the patient should be watched for ICR.
4. Open bite and Pierre Robin patients, although deviating significantly from the norms dentofacially, show a normal vertical mandibular growth rate and pattern.
5. In a normal untreated sample at the end of growth, deeper antegonial notching was correlated with greater lower anterior facial height and steeper mandibular plane angle, although the strength of the relationship was weak.

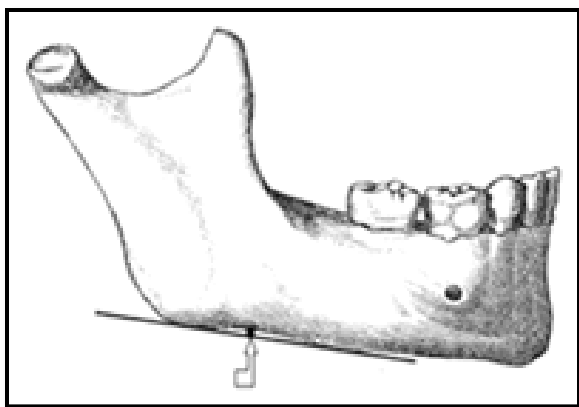


Figure 1. Antegonial notch.

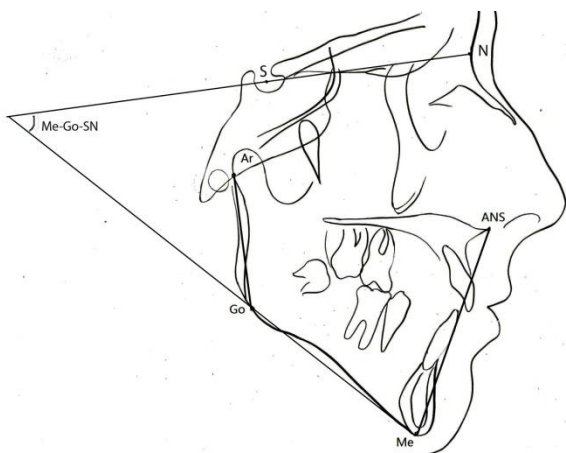


Figure 2. Landmarks and measurements.

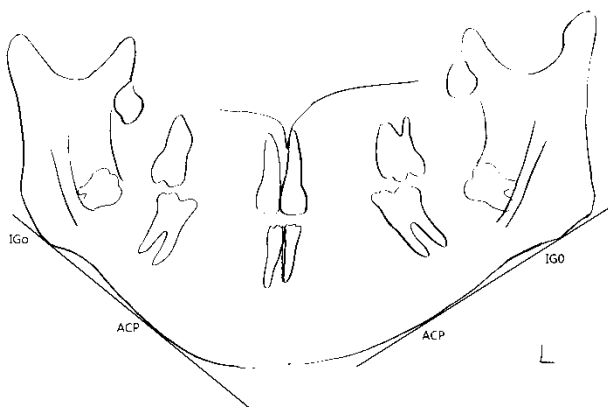


Figure 3. On panoramic radiographs, antegonial notch is measured as the greatest point of convexity in the line connecting anterior convexity point (ACP) with gonion (Go) along the line perpendicular to the ACP-Go line.

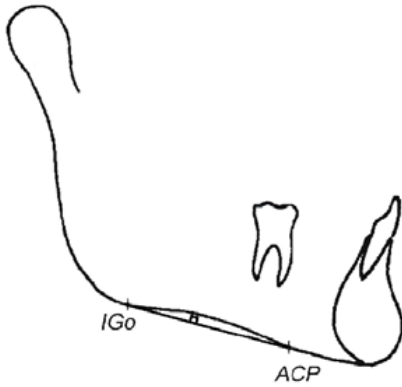


Figure 4. On cephalometric radiographs, antegonial notch is measured as the greatest point of convexity in the line connecting anterior convexity point (ACP) with gonion (Go) along the line perpendicular to the ACP-Go line.

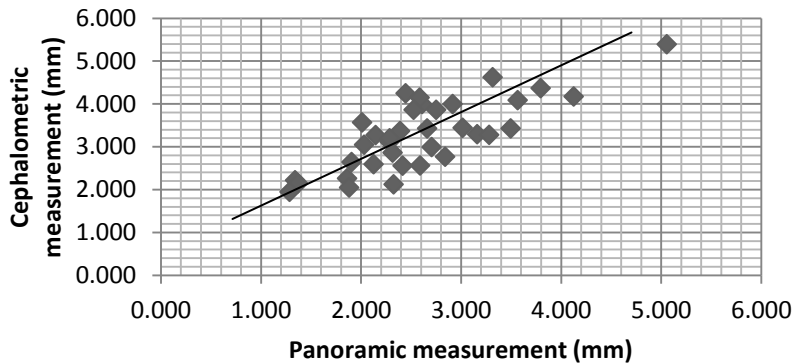


Figure 5. Scatter plot of panoramic means and cephalometric means of left and right side of the antegonial notch depth ( $r=0.786$ ,  $p<0.001$ ). The equation of reduced major axis is the mean cephalometric value =  $1.04 \times$  mean panoramic value +  $0.56$ .

Table 1. Definition of parameters identified in radiographs.

Parameters	Definitions
Panoramic & cephalometric radiographs	
Antegonial Notch (AN)	Point of deepest concavity between anterior convexity and inferior gonion
Anterior Convexity Point (ACP)	Point of greatest convexity along the anterior-inferior border of the mandible
Inferior Gonion (Go)	Point of the greatest convexity along the posterior-inferior border of the mandible
Cephalometric radiographs only	
ANS – Me	Measures anterior lower facial height
ANS (anterior nasal spine)	The tip of the median, sharp bony process of the maxilla at the lower margin of the anterior nasal opening.
Ar (Articulare)	Point of intersection of the inferior cranial base surface and the posterior surface of condylar neck
Ar-Go	Measures posterior facial height
Go (gonion)	The midpoint of mandibular angle
Me (Menton)	The most inferior point on the symphyseal outline.
Nasion	Junction of the nasal and frontal bones at the naso-frontal suture
Sella	Midpoint of sella turcica

Table 2. Descriptive data for panoramic and cephalometric comparison of antegonial notch depth (mm).

	N	Minimum	Maximum	Mean	Std. Deviation
Biggest_Ceph	35	1.95	5.74	3.53	.89
Biggest_PAN	35	1.37	5.41	2.93	.88
Mean_PAN	35	1.29	5.06	2.61	.79
Mean_Ceph	35	1.95	5.40	3.29	.82

Table 3. Descriptive data for patient and their control groups in gender, age, and time span.

Sample Groups	Total (n)	Male (n)	Female (n)	Age T1 (years)	Age T2 (years)	Time span (T2-T1 Age) (years)
Open bite	43	14	29	10.08	16.6	6.52
Control for open bite	43	14	29	10.29	15.53	5.24
Pierre Robin sequence (PRS)	61	28	33	6.82	16.10	9.28
Control for PRS	61	28	33	6.76	15.45	8.69
Idiopathic condylar resorption (ICR)	13	0	13	10.85	16.9	6.05
Control for ICR	26	0	26	10.64	16.3	5.66
Open Bite females matched for ICR	29	0	29	10.42	15.83	5.41

Table 4. Comparison between patient and their control groups for cephalometric means change in variables from T1 to T2 by subtracting measurements from T1 from measurements from T2 in patient and their control groups.

Sample Groups	Antegonial depth T1 (mm)	Antegonial depth T2 (mm)	Changes in antegonial notch depth (mm)	Lower anterior facial height at T1 (mm)	Lower anterior facial height at T2 (mm)	Changes in lower anterior facial height (mm)	Posterior facial height at T1 (mm)	Posterior facial height at T2 (mm)	Changes in posterior facial height (mm)	Mandibular plane angle at T1 (°)	Mandibular plane angle at T2 (°)	Changes in mandibular plane angle (°)
Open bite	2.30 (±0.92)	2.35 (±0.97)	0.05 (±0.68)	65.95 (±6.13)	71.87 <sup>‡</sup> (±7.38)	5.92 (±3.35)	40.71 (±4.05)	45.46 <sup>‡</sup> (±5.82)	4.75 (±4.23)	39.18 (±5.42)	38.92 <sup>‡</sup> (±6.29)	- 0.26 (±4.68)
Control for open bite	1.85* (±0.72)	1.92* (±0.79)	0.07 (±0.49)	64.02 (±6.30)	69.97 <sup>‡</sup> (±8.73)	5.95 (±4.98)	41.55 (±5.12)	46.54 <sup>‡</sup> (±6.14)	4.98 (±3.94)	36.49* (±5.07)	34.97*** <sup>‡</sup> (±4.81)	- 1.52 (±2.41)
Pierre Robin (PRS)	3.13 (±0.97)	3.28 (±1.12)	0.15 (±0.89)	60.30 (±6.47)	70.92 <sup>‡</sup> (±9.09)	10.62 (±7.73)	35.66 (±6.47)	44.03 <sup>‡</sup> (±6.33)	8.37 (±6.24)	45.63 (±9.65)	43.87 <sup>‡</sup> (±10.66)	- 1.76 (±11.34)
Control for PRS	2.16** (±0.81)	2.24** (±0.96)	0.08 (±0.57)	59.72 (±5.67)	69.64 <sup>‡</sup> (±8.59)	9.92 (±6.18)	37.53* (±4.26)	47.48*** <sup>‡</sup> (±6.85)	9.95 (±4.73)	36.23** (±4.26)	34.43*** <sup>‡</sup> (±4.57)	- 1.80 (±2.89)
Idiopathic condylar resorption (ICR)	3.04 (±1.09)	3.51 <sup>‡</sup> (±1.26)	0.47 (±0.36)	66.70 (±11.6)	73.41 <sup>‡</sup> (±11.31)	6.71 (±4.24)	40.18 (±5.48)	41.30 (±5.32)	1.12 (±2.5)	41.30* (±7.2)	46.32*** <sup>‡</sup> (±5.98)	5.02 (±5.33)
Control for ICR	1.84** (±0.81)	1.87** (±0.85)	0.03** (±0.43)	61.56 (±6.16)	67.27* <sup>‡</sup> (±6.74)	5.71 (±3.02)	40.27 (±5.05)	44.64* <sup>‡</sup> (±5.15)	4.37 * (±2.94)	36.75* (±5.58)	35.50*** <sup>‡</sup> (±5.22)	-1.25** (±5.0)
Open Bite matched for ICR	2.17 ** (±0.90)	2.30 ** (±1.03)	0.13 (±0.75)	65.75 (±6.45)	71.46 <sup>‡</sup> (±7.52)	5.71 (±3.54)	40.80 (±3.50)	44.87* <sup>‡</sup> (±5.40)	4.03 * (±3.87)	39.38 (±5.04)	38.43*** <sup>‡</sup> (±5.99)	0.05* (±5.34)

\*P<0.05, \*\*P<0.01, significant between the patient and the control groups

<sup>‡</sup> T2-T1 in the same group, P<0.01

Table 5. Correlations between changes in antegonial notch depth, lower anterior facial height, posterior facial height, and mandibular plane angle in patient and their control groups.

Changes in antegonial notch depth in sample groups (Pearson correlation)	Changes in lower anterior facial height	Changes in posterior facial height	Changes in mandibular plane angle
Open bite	-0.06	0.06	-0.11
Control for open bite	0.26	0.30	0.12
Pierre Robin sequence (PRS)	0.08	0.07	-0.06
Control for PRS	0.36**	0.36**	0.01
Idiopathic condylar resorption (ICR)	0.58*	0.19	0.63*
Control for ICR	-0.01	-0.13	-0.02
Open bite females matched for ICR	0.31	0.48	0.12

\* P<0.05, \*\*P<0.01

Table 6. Correlation between antegonial notch depth at T1 and the changes in other variables.

Antegonial notch depth at T1 (Pearson correlation)	Changes in lower anterior facial height	Changes in posterior facial height	Changes in mandibular plane angle
Control (n=104)	0.15	0.19	0.08
Open bite (n=43)	0.14	0.09	0.11
PRS (n=61)	0.15	-0.02	0.09
ICR (n=13)	0.01	-0.32	0.01

Table 7. Correlation between antegonial notch depth and other variables at T2 in different groups.

Antegonial notch depth at T2 (Pearson correlation)	Lower anterior facial height at T2	Posterior facial height at T2	Mandibular plane angle at T2
Control group (n=104)	0.36**	0.34**	0.18*
Open bite (n=43)	0.18	0.21	0.10
Pierre Robin (n=61)	0.21	0.18	0.12
ICR (n=13)	0.01	0.36	0.02

## References

1. Ahlqvist, J. Eliasson, S. Welander, U. The effect of projection errors on cephalometric length measurements. *European Journal of Orthodontics* 8 (1986) 141-148.
2. Ali IM, Yamada K, Hanada K. Mandibular antegonial and ramus notch depths and condylar bone change. *J Oral Rehabil.*2005;32:1-6.
3. American Association of Orthodontics Foundation. AAOF Legacy Collection. [http://www.cril.org/aaof/aaof\\_home.asp](http://www.cril.org/aaof/aaof_home.asp)
4. Becker MH, Cocco PJ, Converse JM. Antegonial notching of the mandible: an often overlooked mandibular deformity in congenital and acquired disorders. *Radiology.* 1976;121:149-51.
5. Bjork A. Prediction of mandibular growth rotation. *Am J Orthod* 1969 Jun; 55(6): 585-99.
6. Bjork A. The use of metallic implants in the study of facial growth in children: method and application. *Am J phys Anthropol* 1968 Sep; 29(2): 243-54.
7. Byun ES, Ahn SJ, and Kim TW. Relationship between internal derangement of the temporomandibular joint and dentofacial morphology in women with anterior open bite.
8. Cotrim-Ferreira, F., Valle-Corotti, K. M., Lopes, P. , Junqueira, T., Stocco, J. Association between respiratory pattern and mandibular morphology. *Revista de Odontologia da Universidade Cidade de Sao Paulo.* 2009 jan-abr; 21(1): 18-23.
9. Dutra V, Yang J, Devlin H, Susin C. Mandibular bone remodeling in adults: evaluation of panoramic radiographs. *Dentomaxillofac Radio* 2004; 33: 323-8
10. Enlow DH, Bianco HJ, Eklund S. The remodeling of the edentulous mandible. *J Prosthet Dent.* 1976; 36:685-93.
11. Faul, F., Erdfelder, E., Buchner, A., & Lang, A.-G. (2009). Statistical power analyses using G\*Power 3.1: Tests for correlation and regression analyses. *Behavior Research Methods, 41*, 1149-1160.
12. Faul, F., Erdfelder, E., Lang, A.-G., & Buchner, A. (2007). G\*Power 3: A flexible statistical power analysis program for the social, behavioral, and biomedical sciences. *Behavior Research Methods, 39*, 175-191.
13. Ghosh, S., Vengal, M., Pai KM, Abhishek, K. Remodeling of the antegonial angle region in the human mandible: a panoramic radiographic cross-sectional study. *Med Oral Patol Oral Cir Bucal.* 2010 Sep 1;15(5):e802-7.
14. Gidarakou IK, Tallents RH, Kykanides S, Stein S, Moss ME. Comparison of skeletal and dental morphology in asymptomatic volunteers and symptomatic patients with bilateral degenerative joint disease. *Angle Orthod* 2003; 73:71-8
15. Hermann, N., Darvann, T., Dahl, E., and Bolund, S. Craniofacial morphology and growth comparisons in children with robin sequence, isolated cleft palate, and unilateral complete cleft lip and palate. *The Cleft Palate-Craniofacial Journal: July 2003, Vol. 40, No. 4, pp. 373-396.*

16. Hofman MA. 1988. Allometric scaling in paleontology: A critical survey. *Hum Evol* 3: 177-188
17. Huang, G. Stability of anterior open-bite treated with crib therapy. May 1989. Master thesis. University of Washington.
18. Kolodziej RP, Southard TE, Southard KA, Casco JS, Jakobsen JR. Evaluation of antegonial notch depth for growth prediction. *Am J Orthod Dentofacial Orthop* 2002 Apr; 121 (4): 357-63.
19. Jacobson, A. and Jacobson R. Radiographic cephalometry from basics to 3-D imaging. Second edition. Quintessence books. 2006.
20. Kreiborg, S., Bakke, M., Kirkeby, S., Michler, L., Vedtoft, P., Seidler, B., and Moller, E. Facial growth and oral function in a case of juvenile rheumatoid arthritis during an 8-year period.
21. Lambrechts, AH, Harris AM, Rossouw PE, Stander I. Dimensional differences in craniofacial morphologies of groups with deep and shallow mandibular antegonial notching. *Angle Orthod* 1996; 66(4): 265-72.
22. Larheim TA, Svanaes DB. Reproducibility of rotational panoramic radiography: mandibular linear dimensions and angles. *Am J Orthod Dentofacial Orthop*. 1986; 90:45-51.
23. Pirttiniemi P, Peltomaki T, Muller L, and Lunder H. Abnormal mandibular growth and the condylar cartilage. *Eur Journal of Orthod* 21 (2009) 1-11.
24. Preston B, Al-Sehaibany F, Salem O. The morphology of the mandibular antegonial notches and facial symmetry. *J Clin Pediatr Dent*. 2002;26:155-60.
25. Ringold, S., Cron, R.. The temporomandibular joint in juvenile idiopathic arthritis: frequently used and frequently arthritic. *Pediatric Rheumatology* 2009, 7:11.
26. Ronning, O., Valizho, M. 1975. Involvement of the facial skeleton in juvenile rheumatoid arthritis. *Annales de Radiologie* 18: 347-353.
27. Shahabi, M., Ramazanzadeh, B., and Mokhber, N. Comparison between the external gonial angle in panoramic radiographs and lateral cephalograms of adult patients class I malocclusion. *Journal of Oral Science*, Vol. 51, No.3, 425-429, 2009.
28. Singer, C.P., Mamandras, A.H., Hunter, W.S.(1987). The depth of the mandibular antegonial notch as an indicator of mandibular growth potential. *Am J Orthod Dentofacial Orthop* 1987;91:117-24.
29. Suri, S., Ross, R., and Tompson, B. Craniofacial morphology and adolescent facial growth in Pierre Robin sequence. *Am J Orthod Dentofacial Orthop* Vol 137, No. 6, 767-774, June 2010.
30. Van Elslande, D. C., Russett, S. J, Major, P. W., Flores-Mir, C. Mandibular asymmetry diagnosis with panoramic imaging. *Am J Orthod Dentofacial Orthop* 2008 July; 134 (2): 183-192.

31. Xie Q, Soikkonen K, Wolf J, Mattila K, Gong M, Ainamo A. Effect of head positioning in panoramic radiography on vertical measurements: an in vitro study. *Dentomaxillofac radio*. 1996; 25:61-6
32. Yamada, K, Hiruma Y, Hanada K, Hayashi T, Koyama J, Ito J. Condylar bony change and craniofacial morphology in orthodontic patients with TMJ disorder (TMD) symptoms: A pilot study using helical computed tomography and magnetic resonance imaging. *Clin Orthod Res* 1999;2:133-142.

Open bite	Sex	T1Age (month)	T2Age (month)	Antegonial notch depth (T1)	Antegonial notch depth (T2)	Lower anterior facial height (mm)
1	F	128	299	1.02	0.63	56.84
2	F	124	288	1.26	1.99	64.99
3	F	101	200	2.46	2.69	61.17
4	F	129	176	3.05	3.65	72.93
5	F	168	206	1.56	2.31	70.23
6	F	161	208	0.97	0.91	72.42
7	F	102	216	1.95	2.3	61.15
8	F	89	132	1.1	1.2	58.98
9	F	97	216	2.51	4.35	56.55
10	F	177	216	1.9	3.52	79.99
11	F	142	194	0.6	0.92	64.12
12	F	190	206	1.83	2.54	70.54
13	F	143	204	1.58	1.55	65.85
14	F	103	131	3.95	4.15	63.73
15	F	108	169	1.55	1.77	65.72
16	F	103	167	2.28	2.18	56.85
17	F	87	150	2.28	1.15	56.4
18	F	155	210	1.13	0.95	68.7

19	F	188	258	1.57	2.5	70.52
20	F	91	186	3.3	2.99	58.31
21	F	107	228	1.53	1.13	58.76
22	F	132	180	3.11	3.55	71.92
23	F	101	253	2.81	2.94	64.8
24	F	117	208	2.27	2.37	67.58
25	F	120	300	2.69	3.68	72.37
26	F	129	163	3.07	1.86	68.85
27	F	88	147	4.02	3.1	64.87
28	F	94	141	3.07	1.64	63.17
29	F	147	207	2.42	2.43	78.37
30	M	84	126	1.75	1.26	61.49
31	M	101	138	2.8	2.46	67.34
32	M	102	136	2.89	2.35	65.72
33	M	99	156	2.31	2.25	63.03
34	M	96	152	2.43	1.86	65.87
35	M	106	168	2.58	2.43	67.85
36	M	92	164	3.4	3.73	58.11
37	M	117	275	3.27	3.14	61.74
38	M	107	168	2.88	3.34	71.98
39	M	145	229	2.92	2.5	74.76

40	M	108	210	1.64	2.25	61.81
41	M	143	198	1.15	1.05	62.17
42	M	117	218	4.77	3.79	69.13
43	M	164	360	1.34	1.48	77.96

Open bite	Lower				
	anterior	Posterior	Posterior	Mandibular	Mandibular
	facial	facial height	facial height	plane angle T1	plane angle T2
	height (mm)	T1 (mm)	T2 (mm)	( $^{\circ}$ )	( $^{\circ}$ )
1	63.85	41.61	45.02	35.9	35.2
2	74.3	46.6	53.96	50	54.3
3	74.03	39.49	47.25	33.6	33
4	80.37	43.06	48.64	41.7	40
5	72.95	43.97	44.11	37.8	35.8
6	77.18	44.75	45.36	35.2	37.7
7	63.96	38.92	43.23	35.4	34.6
8	61.91	37.33	41.94	39.7	37.3
9	65.34	37.88	48.57	37.3	35.6
10	87.83	45.93	57.34	45.2	43.6
11	71.67	38.48	45.52	40.8	46.9
12	70.65	44.5	45.64	40.7	41.7
13	69.64	45.68	49.92	33.9	33.6

14	65.74	37.74	39.54	36.8	36
15	73	44.37	48.86	36	35.1
16	64.3	39.26	41.23	40.8	44.7
17	58.4	36.92	37.81	32.4	30.4
18	69.73	43.43	45.36	35.8	33.5
19	79.23	40	45.51	39.5	43
20	59.76	34.95	42.69	36.1	32.3
21	69.38	39.53	45.12	31.2	33.3
22	78.59	41.88	44.58	40.8	47.3
23	74.05	38.23	44.68	42.7	40.4
24	77.37	35.14	35.37	45.8	47.7
25	76.4	44.23	44.01	41.8	40.1
26	75.53	45.28	50.44	37.3	37.1
27	64.53	36.9	39.96	47.1	43.1
28	65.12	37.22	38.13	38.4	39.6
29	87.56	40.44	42.37	52.4	50.7
30	64.74	35.96	40.7	36.5	38.4
31	71.4	37.28	40.99	49.1	49.8
32	70.59	46.33	49.91	33.6	35.6
33	67.02	42.63	43.91	35.2	37.8
34	68.8	40.65	42.76	43	37.4
35	73.9	44.09	48.5	32.5	34.5
36	61.14	37.13	41.59	35.5	34.7

37	66.39	40.01	48.43	35.7	30.4
38	81.66	42.02	52.41	35.3	34.2
39	84.59	53.9	64.55	29.5	25.8
40	71.19	35.45	44.97	44.6	40.2
41	73.89	35.14	43.97	39.9	40.3
42	78.23	38	49.95	39.8	37.6
43	84.56	38.48	39.34	52.5	53.3

Control for open bite	Sex	T1 Age (month)	T2 Age (month)	Antegonial notch T1 (mm)	Antegonial notch T2 (mm)	Lower anterior facial height T1 (mm)
1	F	120	216	1.64	1.57	58.19
2	F	120	162	1.88	1.65	53.8
3	F	127	163	1.82	2.11	59.09
4	F	125	150	2.78	2.88	69.41
5	F	120	181	3.27	3.43	60.2
6	F	126	199	2.27	1.94	72.82
7	F	127	211	1.14	0.85	56.43
8	F	119	180	2.5	2.64	67.83
9	F	155	199	2.5	2.58	63.5
10	F	126	144	0.9	1.31	63.6
11	F	119	184	0.63	0.6	71.98
12	F	126	192	2.1	2.45	63.97
13	F	126	181	2.82	2.76	63.68

14	F	121	180	0.63	0.5	59.16
15	F	120	193	1.07	1.51	47.6
16	F	120	193	2.09	2.2	48.78
17	F	119	205	1.25	1.06	61.02
18	F	119	216	1.87	1.48	60.05
19	F	120	216	1.49	1.96	60.98
20	F	120	192	1.02	1.67	58.48
21	F	120	192	2.17	1.21	59.41
22	F	130	192	2.64	3.23	57.4
23	F	132	192	3.63	3.18	68.74
24	F	120	222	0.92	1.09	66.51
25	F	120	205	1.37	1.14	62.81
26	F	120	216	1.33	1.6	65.15
27	F	117	161	1.82	1.5	61.62
28	F	119	202	2.01	2.45	67.7
29	F	108	144	1.2	1.8	62.25
30	F	117	219	1.82	1.8	64.02
31	M	133	200	1.85	2.13	69.87
32	M	120	216	2.96	2	65.21
33	M	120	171	1.53	1.1	70.08
34	M	131	155	1.53	2	64.36
35	M	108	179	1.03	1.2	62.53
36	M	119	144	2.51	2.86	70.08
37	M	132	180	2.05	1.92	70.29
38	M	119	219	2.35	3.42	67.11

39	M	114	168	1	0.8	65.74
40	M	120	180	1.7	2.03	69.64
41	M	119	181	2.29	1.91	77.24
42	M	131	168	2.65	2.8	71.52
43	M	120	168	1.66	2.27	73.16

Control for open bite	Lower anterior facial height T2 (mm)	Posterior facial height T1 (mm)	Posterior facial height T2 (mm)	Mandibular plane angle T1 (°)	Mandibular plane angle T2 (°)
1	61.21	46.82	50.13	28.4	24.8
2	63.65	35.6	42.77	32.3	33.6
3	59.86	40.07	42.62	34.5	34.1
4	72.14	43.7	45.98	36.4	36.4
5	65.34	45.76	54.6	21.9	21.7
6	76.01	40.3	40.3	43.9	44.4
7	63.82	44.55	49.09	31.3	33.2
8	75.17	43.13	48.77	39.9	37.2
9	65.55	41.79	44.02	34.9	30.3
10	65.7	41.77	41.49	37.1	37.4
11	79.91	48.17	51.03	38.7	39.1
12	71.23	38.29	40.69	37.9	38.6
13	72.91	39.07	47.37	37.8	36.5

14	66.15	46.7	49.82	30.1	31.8
15	53.29	28.6	33.54	37	33.1
16	55.01	32.05	33.35	39.9	39.7
17	66.94	32.83	39.49	41.7	36.1
18	67.05	34	43.31	41	37.9
19	62.84	40.62	45.35	39.9	37.7
20	67.5	47.42	47.45	33.8	34.7
21	62.57	35.25	41.12	47.2	45.1
22	62.49	42.18	46.88	29.2	28.7
23	72.32	40.55	44.83	43.5	40.2
24	78.66	40	51.31	41.5	35.9
25	65.98	36.86	40.42	35.5	34.9
26	75.69	40.9	44.82	40.1	39.7
27	67.63	39.36	43.25	31.4	32
28	68.82	44.45	47.15	36.4	34.4
29	65.94	40.35	40.84	36.4	38.5
30	70.63	39.36	46.75	36.4	34.9
31	76.92	45.44	54.08	31.6	25.6
32	70.37	45.52	49.92	36.3	34.1
33	75.74	41.57	47.24	34.3	33
34	67.17	40.23	44.79	34.5	32
35	69.86	38.38	49.21	34.3	29
36	73.34	40.7	42.14	41.2	39.9

37	81.64	46.16	57.21	39.7	36.7
38	82.01	46.8	59.28	31.7	28.9
39	69.65	46.58	51.08	33.3	32.1
40	77.6	40.25	48.06	37.7	35.8
41	90.29	39.05	52.28	43	41.3
42	75.69	48.83	50.25	31.3	32.1
43	76.48	56.48	57.27	44	40.5

Pierre Robin	Sex	T1 Age (months)	T2 Age (month)	Antegonial notch depth T1 (months)	Antegonial notch depth T2 (months)	Lower anterior facial height T1 (mm)
1	M	208	216	2.42	2.47	65.6
2	M	214	325	4.28	7.04	63.89
3	M	38	100	2.65	2.63	52.41
4	M	72	135	2.47	2.14	55.89
5	M	100	213	4.37	3.56	59.64
6	M	67	215	2.53	2.35	61.42
7	M	36	172	3.01	2.35	63.39
8	M	78	133	1.86	1.89	56.12
9	M	120	151	4.24	4.79	59.64
10	M	46	187	3.34	3.2	57.27
11	M	160	247	3.54	3.75	71.97

12	M	87	225	2.38	3.37	63.37
13	M	45	66	2.69	3.32	60.26
14	M	46	80	3.95	4.03	59.56
15	M	87	166	2.98	3.72	58.51
16	M	139	182	2.69	3.08	67.03
17	M	78	122	2.58	3.13	62.11
18	M	64	186	4.18	2.62	60.31
19	M	198	230	2.85	2.33	75.57
20	M	52	203	5.22	5.15	53.22
21	M	71	237	4.13	4.09	52.84
22	M	70	200	3.64	4.39	69.02
23	M	60	185	2.95	4.86	60.21
24	M	62	201	3.24	5.5	60.46
25	M	63	187	4.4	4.51	65.62
26	M	66	180	2.5	3.11	53.28
27	M	78	179	2.63	2.66	57.21
28	M	67	216	2.71	3.29	60.09
29	F	190	250	3.87	3.98	67.64
30	F	68	338	2.41	3.86	65.31
31	F	61	321	2.77	3.65	60.43
32	F	60	111	3.41	4.24	63.43

33	F	53	88	2.8	2.9	48.66
34	F	58	200	4.47	3.66	58.62
35	F	90	160	1.86	2.5	61.07
36	F	57	166	2.09	2.68	52.61
37	F	51	210	3.52	2.43	58.15
38	F	125	222	3.35	3.49	79.15
39	F	51	185	3.03	2.38	57.5
40	F	71	216	4.11	3.95	64.91
41	F	64	90	1.76	2.51	58.09
42	F	90	191	2.35	3.57	60.55
43	F	91	175	2.35	3.45	61.28
44	F	63	247	2.34	2.56	50.58
45	F	79	197	4.89	3.79	63.39
46	F	78	244	1.76	1.95	63.15
47	F	94	226	3.73	2.05	61.42
48	F	59	216	3.62	4.17	53.63
49	F	61	210	2.65	2.5	59.11
50	F	62	199	3.22	1.42	54.67
51	F	81	191	3.24	3.34	61.71
52	F	60	210	2.5	4.07	52.01
53	F	71	215	2.61	3.08	56.82

54	F	69	210	5.92	4.37	75.06
55	F	61	218	3.03	2.49	57.96
56	F	61	176	2.39	2.53	59.49
57	F	85	171	3.59	2.98	65.95
58	F	85	198	2.73	2.8	58.19
59	F	117	228	3.19	3.75	48.18
60	F	82	192	2.76	1.83	61.27
61	F	72	172	2.41	2.05	52.37

Pierre Robin	Lower anterior facial height T2 (mm)	Posterior facial height T1 (mm)	Posterior facial height T2 (mm)	Mandibular plane angle T1 (°)	Mandibular plane angle T2 (°)
1	67.99	40.68	40.38	38.1	34.5
2	77.73	42.75	51.81	31.5	28.2
3	56.49	29.68	35.08	44.8	41.8
4	61.77	37.58	43.47	36.4	38.8
5	75.77	34.36	52.36	44.4	41.7
6	81.04	32.71	41.35	56.5	63.4
7	81.83	36.67	44.21	50.3	44.5
8	59.46	12.55	15.54	60	56.4
9	64.52	46.1	52.12	60.2	55.6
10	71.81	35.48	47.61	65.3	61.3
11	75.16	39.06	43.87	41.8	36.8

12	79.88	41.52	54.54	33.7	31.1
13	65.24	35.69	36.52	40.3	43.9
14	67.58	37.12	37.68	39.6	46.1
15	75.45	33.77	46.24	58.4	57.6
16	83.25	41.81	48.12	45.5	40.6
17	71.41	36.9	39.61	49.8	51.5
18	78.05	38.84	48.49	34.7	39.05
19	83.07	40.8	45.23	46.7	50.3
20	62.99	39.16	51.62	43.1	41.7
21	61.11	38.76	48.83	43.2	40.9
22	84.1	35.08	47.09	50.3	42.8
23	79.87	36.11	50.86	53.4	46.5
24	74.08	32.4	44.54	43.7	41.1
25	71.01	40.59	42.22	44	41.6
26	60.32	40.34	51.95	44.7	41.9
27	68.61	33.56	43.03	48.8	41.7
28	79.27	34.83	42.44	46.8	45.3
29	68.5	42.13	44.44	40.8	39.4
30	78.45	37.67	52.93	46.6	43.5
31	77.78	32.2	41.83	44.2	48.9
32	69.85	35.31	42.8	45	40.3
33	57.51	32.21	42.89	27.7	23.6
34	67.12	31.31	41.29	40	36.9

35	66.98	28.97	35.12	45.6	49.8
36	57.35	34.49	42.63	33	35.1
37	73.28	30.49	42.84	51.8	46.7
38	89.5	31.84	46.33	71	67.8
39	69.11	31.72	41.47	34.9	30.2
40	81.08	32.14	41.68	45.3	43.9
41	65.72	36.41	41.41	47.1	50.5
42	71.8	41.36	45.8	48.1	48.6
43	70.71	35.32	41.45	44.1	45.2
44	58.16	35.24	44.07	41.5	43.1
45	69.94	36.19	45.08	42.1	37.1
46	78.18	33.65	45.84	60.7	58.1
47	66.12	29.91	35.74	53.1	49.9
48	60.93	31.85	40.23	47.1	47.4
49	73.89	34.79	46.22	41.4	34
50	66.1	34.17	41.49	36.7	40.5
51	68.09	33.68	45.97	50.1	43.2
52	64.3	32.08	45.17	35.6	33.2
53	70.96	33.76	41.09	37	39.2
54	85.44	44.37	51.63	58.2	61.4
55	76.65	30.35	40	50.4	50.7
56	70.5	26.75	36.82	47.5	40.8
57	70.49	41.74	47.37	35.6	31.5

58	67.46	32.85	41.44	50.7	46.3
59	66.55	58.9	67.53	48	43.6
60	70.13	36.39	40.38	48.4	44.1
61	58.57	30.1	37.98	38.5	35.1

Control for PRS	Sex	T1 Age (months)	T2 Age (months)	Antegonial notch depth T1 (mm)	Antegonial notch depth T2 (mm)	Lower anterior facial height T1 (mm)
1	F	60	162	1.69	1.65	53.15
2	F	90	163	2.33	2.11	57.63
3	F	53	150	2.73	2.78	71.75
4	F	72	181	3.37	3.43	57.08
5	F	79	199	2.33	2.86	65.71
6	F	91	211	1.29	0.85	55.31
7	F	67	161	1.55	1.56	62.12
8	F	84	180	2.96	2.64	64.15
9	F	72	155	3.26	3.58	62.26
10	F	54	144	2.58	3.31	58.1
11	F	84	144	2.54	2.75	63.11
12	F	72	184	1.37	1.6	65.71
13	F	59	144	1.73	1.8	59.69
14	F	62	173	2.57	2.17	54.57
15	F	98	163	1.59	1.6	55.37

16	F	80	145	1.59	0.92	55.96
17	F	95	187	2.33	2.17	60.32
18	F	81	172	1.76	1.25	62.92
19	F	91	221	1.77	2.09	56.28
20	F	89	154	1.32	1.61	63.06
21	F	45	156	2.29	1.6	56.26
22	F	51	180	1.48	1.5	52.22
23	F	96	193	1.35	1.51	47.4
24	F	96	193	1.93	2.2	46.79
25	F	85	205	1.43	1.06	58.38
26	F	73	216	1.06	1.48	56.51
27	F	72	216	2.27	1.96	57.53
28	F	84	216	1.99	1.67	56.51
29	F	96	192	2.21	1.21	55.81
30	F	95	192	2.21	3.53	56.56
31	F	96	193	1.07	0.92	64.37
32	F	97	192	3.26	3.18	67.05
33	F	54	220	1.37	1.09	59.21
34	M	95	216	2.67	3.34	62.27
35	M	48	155	2.42	2.3	56.49
36	M	72	179	1.44	1.2	59.33
37	M	49	144	2.96	2.96	63.3
38	M	60	180	3.49	3.9	60.43
39	M	90	168	1.7	1.8	63.11
40	M	83	180	1.83	2.73	63.68

41	M	95	168	2.84	2.8	67.46
42	M	84	168	2.27	2.27	64.94
43	M	47	143	4.43	3.43	66.93
44	M	90	156	2.29	2.82	66.48
45	M	59	119	2.22	2.3	61.64
46	M	83	193	5.28	4.82	62.01
47	M	103	229	2.54	2.89	62.18
48	M	109	170	2.14	2.2	58.33
49	M	95	216	1.82	2.65	60.57
50	M	119	209	3.18	3.52	65.12
51	M	104	236	2.58	3.11	63.14
52	M	51	180	1.83	2.41	56.73
53	M	96	216	0.97	0.92	44.97
54	M	97	218	1.85	2.37	49.37
55	M	95	218	1.14	0.76	45.84
56	M	96	205	1.27	1.42	56.98
57	M	96	222	1.82	1.51	62.11
58	M	96	216	2.35	2.36	67.03
59	M	95	215	2.23	3.33	68.02
60	M	84	216	1.33	2.2	63.96
61	M	84	218	2.58	2.88	61.65

Control for PRS	Lower anterior	Posterior	Posterior	Mandibular	Mandibular plane angle T2 (°)
	facial height T1 (mm)	facial height T1 (mm)	facial height T2 (mm)	plane angle T1 (°)	
1	63.65	34.25	42.77	31.1	33.6
2	69.86	35	42.62	37.4	34.1
3	78.14	45.09	47.92	37.6	37.7
4	65.64	43.02	59.2	27.6	21.7
5	76.17	35.75	46.75	42.4	45.2
6	63.82	39.34	49.09	32.5	33.2
7	67.63	36.93	44.25	35.7	32.9
8	75.17	37.69	48.77	42.8	37.2
9	65.55	33.59	44.02	38.8	30.3
10	65.7	37.37	44.49	38.8	37.4
11	68.82	42.35	48.15	32.1	34.4
12	79.91	39.38	51.03	38.4	39.1
13	65.94	35.59	40.84	38.5	38.5
14	67.48	37.1	47.06	33	31.6
15	60.13	33.94	39.18	33.2	32.2
16	61.12	36.77	42.88	33.3	32.5
17	63.99	39.06	52.07	35.7	30.5
18	73.69	35.24	42.5	38.9	40.3
19	68.97	37.31	47.09	30.8	31.5
20	71.35	41.31	47.34	36.6	41.4
21	62.63	32.35	42.46	42.2	35.7
22	66.15	39.96	49.82	27.8	31.8
23	53.29	27.7	33.54	37.7	33.1
24	55.01	27.26	33.35	40.3	39.7
25	66.94	29.88	39.49	40.3	36.1
26	67.05	31.32	43.31	41	37.9
27	62.84	38.88	45.35	38.4	37.7
28	67.5	40.5	47.45	34.7	34.7

29	62.57	32.95	41.12	46	45.1
30	67.49	37.17	49.37	30.8	28.7
31	70.92	39.52	45.92	35.6	31
32	72.32	39.27	44.83	43.5	40.2
33	75.66	35.57	51.31	41.1	35.9
34	85.27	41.83	67.04	35.5	33.6
35	65.17	37.09	44.79	30.9	32
36	69.86	34.66	49.21	37.3	29
37	72.34	34.03	42.14	40.5	39.9
38	71.64	39.1	50.52	37.5	34.1
39	70.65	45	53.08	35.9	32.1
40	77.6	40.2	48.06	33.9	35.8
41	75.69	44.13	51.25	33.9	33.1
42	74.48	42.56	61.27	40.4	38.5
43	76.76	34.07	42.18	47.2	45.7
44	71.49	42.25	49.11	39.3	34.2
45	69.1	36.38	42.19	39.6	37.8
46	79.79	38.69	52.13	33.7	30.7
47	77.17	35.27	51.86	31.6	27.1
48	63.76	36.2	43.21	31	30.6
49	66.9	38.73	47.1	31.8	29.9
50	76.95	40.52	46.16	37.1	37.2
51	74.22	44.45	57.32	36.2	34.9
52	73.05	36.53	49.02	33.5	38.5
53	54.39	31.94	41.49	29	24.7
54	58.98	29.91	38.62	35.3	31.9
55	50.86	30.72	36.34	33.1	30.7
56	69.96	38.67	54.2	34.8	31.3
57	78.34	42.11	54.48	31.2	30.9
58	81.79	40.57	59.67	39.1	33.8
59	82.52	43.74	58.15	33.9	30.9

60	79.61	43.4	58.62	37.9	34.8
61	76.67	37.44	51.97	34.6	33.4

Idiopathic condylar resorption	Sex	T1 Age (months)	T2 Age (months)	Antegonial notch depth T1 (mm)	Antegonial notch depth T2 (mm)	Lower anterior facial height T1 (mm)
1	F	140	162	6.11	6.51	59.85
2	F	116	231	3.6	4.58	62.5
3	F	128	275	2.92	3.69	64.19
4	F	125	154	3.65	4.77	64.4
5	F	161	201	2.32	2.42	52.69
6	F	98	176	1.62	1.98	48.71
7	F	102	202	2.57	2.68	73.68
8	F	94	189	2.5	2.75	68.01
9	F	108	190	2.9	3.75	58.96
10	F	168	174	2.46	2.5	91.5
11	F	135	254	3.44	3.98	80.17
12	F	114	195	2.34	2.43	64.83
13	F	203	232	3.08	3.63	77.55

Idiopathic condylar resorption	Lower anterior facial height T2 (mm)	Posterior facial height T1 (mm)	Posterior facial height T2 (mm)	Mandibular plane angle T1 (°)	Mandibular plane angle T2 (°)	Gonial angle T1 (°)	Gonial angle T2 (°)
1	63.98	33.19	37.09	48.6	49.3	121.3	118.8
2	77.16	42.54	40.75	41.6	53.4	128.9	128.1
3	76.14	41.28	42.72	39.2	48.2	129.6	127.5

4	69.09	45.18	50.2	26.94	31.4	130.7	128.9
5	54.41	35.18	36.69	38.8	41.2	122.9	120.3
6	57.54	30.47	32.33	40.2	49.1	144	141
7	77.4	41.21	39.18	47.8	51.4	132	127.4
8	73.83	39.35	36.93	40.6	43.9	129.6	130.8
9	69.65	42.32	43.75	34.3	43.2	129.7	127.5
10	93.98	40.94	40.73	42.2	43	126.2	126.2
11	90.83	44.85	47.8	41.6	48.7	124.4	122.2
12	71.14	35.28	39.43	45.1	45.9	134.6	136.2
13	79.17	50.55	49.25	50	53.5	131	129.4
				Antegonial	Antegonial	Lower anterior	
Control		T1 Age	T2 Age	notch depth	notch depth T2	facial height T1	
for ICR	Sex	(months)	(months)	T1 (mm)	(mm)	(mm)	
1	F	120	216	1.64	1.57	58.19	
2	F	120	162	1.88	1.65	53.8	
3	F	127	163	1.82	2.11	59.09	
4	F	125	150	2.78	2.88	69.41	
5	F	120	181	3.27	3.43	60.2	
6	F	126	199	2.27	1.94	72.82	
7	F	127	211	1.14	0.85	56.43	
8	F	119	180	2.5	2.64	67.83	
9	F	155	199	2.5	2.58	63.5	
10	F	126	144	0.9	1.31	63.6	
11	F	119	184	0.63	0.6	71.98	
12	F	126	192	2.1	2.45	63.97	
13	F	126	181	2.82	2.76	63.68	

14	F	121	180	0.63	0.5	59.16
15	F	120	193	1.07	1.51	47.6
16	F	120	193	2.09	2.2	48.78
17	F	119	205	1.25	1.06	61.02
18	F	119	216	1.87	1.48	60.05
19	F	120	216	1.49	1.96	60.98
20	F	120	216	1.02	1.67	58.48
21	F	120	192	2.17	1.21	59.41
22	F	130	192	2.64	3.23	57.4
23	F	132	192	3.63	3.18	68.74
24	F	120	222	0.92	1.09	66.51
25	F	120	205	1.37	1.14	62.81
26	F	120	216	1.33	1.6	65.15

Control for ICR	Lower anterior facial height T2 (mm)	Posterior facial height T1 (mm)	Posterior facial height T2 (mm)	Mandibular plane angle T1 (°)	Mandibular plane angle T2 (°)	Gonial angle T1 (°)	Gonial angle T2 (°)
1	61.21	46.82	50.13	28.4	24.8	113.3	110.6
2	63.65	35.6	42.77	32.3	33.6	123.5	122.2
3	59.86	40.07	42.62	34.5	34.1	132.7	134
4	72.14	43.7	45.98	36.4	36.4	132.8	134.7
5	65.34	45.76	54.6	21.9	21.7	122.7	121.7
6	76.01	40.3	40.3	43.9	44.4	133.2	134
7	63.82	44.55	49.09	31.3	33.2	125.9	121.1

8	75.17	43.13	48.77	39.9	37.2	124.2	125
9	65.55	41.79	44.02	34.9	30.3	121.8	120.8
10	65.7	41.77	41.49	37.1	37.4	127.4	127.1
11	79.91	48.17	51.03	38.7	39.1	121.3	120.5
12	71.23	38.29	40.69	37.9	38.6	123	121.4
13	72.91	39.07	47.37	37.8	36.5	123.1	122.3
14	66.15	46.7	49.82	30.1	31.8	124.7	125.4
15	53.29	28.6	33.54	37	33.1	120.3	117.8
16	55.01	32.05	33.35	39.9	39.7	141	140.2
17	66.94	32.83	39.49	41.7	36.1	134.3	130.4
18	67.05	34	43.31	41	37.9	132.1	129.8
19	62.84	40.62	45.35	39.9	37.7	134.9	133.2
20	67.5	47.42	47.45	33.8	34.7	129.9	130.2
21	62.57	35.25	41.12	47.2	45.1	138.8	137.2
22	62.49	42.18	46.88	29.2	28.7	125.2	121.4
23	72.32	40.55	44.83	43.5	40.2	128.8	126.3
24	78.66	40	51.31	41.5	35.9	135.6	131.6
25	65.98	36.86	40.42	35.5	34.9	134.1	131.9
26	75.69	40.9	44.82	40.1	39.7	136.8	134.6